

Case Report**A Massive Gastric Trichobezoar In a Young Female, a Case Report**

Basem Badwan¹, Shadi Awad², Mohammad Al-Share³, Mohammad Abu-Jeyyab^{4*}, Hanan Al-Asbahi⁵, Michleen Al-Awabdeh⁶, Maysaa Al-Khalailah⁷

¹G.Surgery consultant, Al-Basheer Hospital, Amman, Jordan

²G.Surgery specialist, Al-Basheer Hospital, Amman, Jordan

³FEBS, Albasheer Hospitsl, Amman, Jordan

⁴MD, Mutah University, Amman, Jordan

⁵G. Surgery Resident, Albasheer Hospital, Amman, Jordan

⁶MD, JUST, Amman, Jordan

⁷MD, BAU, Amman, Jordan

*Corresponding Author: Mohammad Abu-Jeyyab, E-mail: mabujeyyab@yahoo.com

ARTICLE INFO*Article history*

Received: April 02, 2022

Accepted: May 26, 2022

Published: July 31, 2022

Volume: 10 Issue: 3

Conflicts of interest: None.

Funding: None.

Key words:

Trichobezoar,

Trichophagia,

Trichotillomania,

Gastric outlet obstruction,

Young,

Massive

ABSTRACT

Trichobezoar is a rare condition caused by the accumulation of foreign material, specifically hair, into the gastrointestinal tract. Underlying psychiatric disorders are common among patients diagnosed with bezoars. This condition is most commonly associated with trichophagia, trichotillomania might also be present. Typically, this disorder is acquainted in adolescent females who complain of alopecia, along with an upper abdominal mass which might cause gastric outlet obstruction. However, many cases of Trichobezoars of different ages, including infants, have been reported. In this case report, a case of an 18-year-old female with gastric outlet obstruction is demonstrated.

INTRODUCTION

Gastric bezoars represent a medical condition; in which the presence of foreign material takes place in the stomach. Bezoars usually form a compact mass filling the gastric cavity. This condition is categorized according to the nature of the aggregated foreign substance. For example, those composed of plant matter are known as phytobezoars. Trichobezoars represent the presence of hair, pharmacobezoars are related to bezoars comprised of medications, and so on (e.g., tissue paper or Styrofoam) (1).

Trichobezoar occurs when hair; usually an individual's hair, is accumulated in the gastrointestinal tract; most commonly in the stomach. (2) It is caused by trichotillomania; a psychiatric disorder featured by irresistible, recurrent urges to pull out one's hair. This may involve hair of the scalp, eyelashes, eyebrows, or anywhere in the body. Consequently resulting in visible hair loss. Human hair has a smooth surface which makes it hard to be digested as well as difficult

for peristalsis; hence, the formation of trichobezoars takes place. In that, they accumulate between the mucosal folds of the stomach. Over a period of time, continuous ingestion of hair leads to the impaction of hair together with mucus and food and then the trichobezoar is formed. Though Trichobezoar might be confined to the stomach, it may extend to the small intestine or beyond. Trichobezoar that passes down the pylorus and reaches the small intestine, is medically labeled as Rapunzel syndrome (3).

The incidence of this condition is extremely rare. In addition, the rate of prevalence varies from 0.06% to 4%. (20) Ultimately, 90 % of cases occur in women, and 80 % of these cases occur in those under 30 years of age and are linked to anxiety behavior, emotional disturbances, and psychiatric disorders (5).

Mostly, this rare condition is not early diagnosed as it is initially asymptomatic. However, it may lead to severe complications as it continues to increase in size and weight

without self-perception of perpetual hair ingestion. Associated medical complications include gastric mucosal erosion, ulceration, and even perforation of gastric or intestinal walls. Moreover, intussusception, obstructive jaundice, protein-losing enteropathy, pancreatitis, and even death have been reported in the literature as complications of (unrecognized) trichobezoar (6,7,9,10).

CASE PRESENTATION

A 19-year-old female patient; who is a known case of hypothyroidism for which levothyroxine 50mg was prescribed by her family doctor, presented to the emergency department complaining of complete constipation for several days prior to the presentation; recurrent episodes of vomiting and chronic abdominal pain were also reported by the patient. Loss of weight along with the main complaint is elicited. In which the patient claims the presence of unintentional loss of more than 30 kg within 6 months. Clinical examination reveals that the patient had looked pale, ill, below average total body weight with palpable epigastric mass extending down to the umbilicus. Secondary microcytic anemia with hemoglobin of 8.0 gm/dL, mean corpuscular volume (MCV) of 51.3 μm^3 , mean corpuscular hemoglobin (MCH) of 16.0 pgm, and mean corpuscular hemoglobin concentration (MCHC) of 31.1 g/d due to chronic malnutrition was found in laboratory tests. Other biochemistry and serology tests were normal including Tumor markers, Thyroid Stimulating Hormone, and free T4 levels. Plain abdominal x-ray was performed (Figure 1). Ultrasonography was also obtained which reported non-specific findings; dilated stomach with acoustic shadow. As a result of the unspecific symptoms and initial radiological studies, abdominal computed tomography scanning (CAT scan) with contrast was done to show the presence of huge heterogeneous gastric intraluminal mass with mottled gas pattern extending to pylorus along with distention of the second part of duodenum with air-fluid level (Figure 2). Up to this point, clinical, laboratory, and radiology findings were ultimately suggestive of gastric trichobezoar. For further confirmation, upper endoscopy was done

to disclose gastric-confined large trichobezoar (Figure 3). Consequently, laparotomy and subsequent gastrostomy were performed to extract a huge hairy compact mass; 6.2 kg in weight (Figure 4). Post-operative recovery passed smoothly with satisfactory outcome. Psychiatric follow up with a related planned therapeutic regimen were recommended as the patient was referred to the addressed department.

DISCUSSION

Trichobezoar is an accumulation of hair in the alimentary tract. (11) It most commonly forms in the stomach, but may extend into the duodenum and small bowel in what is called "Rapunzel Syndrome". (12) Due to the enzyme-resistant properties of human hair and its slippery surface, it resists digestion as well as peristalsis. Therefore, it accumulates between the gastric mucosal folds. Over the time, and with the continuous ingestion of hair, it gets impacted with food, mucus, and air, forming a cemented mass known as trichobezoar (13).

A teenage girl with long hair is the typical patient of such illness (11), but that doesn't exclude other age groups or sexes, as reported by Sood et al, and Pace et al (14,15) respectively. It might stem from any sort of abuse with resultant anxious behaviours, emotional, and psychological damage, as presented by EL Castrillón Peña et al (5).

Since trichobezoars are basically a hair ball entangled with undigested food in the digestive tract, they are generally asymptomatic unless they reach a substantial size, a large trichobezoar measuring 6.200 grams was described by Hamidi et al (16), or if they cause obstruction of the GIT (11). When symptomatic, a palpable abdominal mass is the most common complaint constituting over 80% of cases, epigastric discomfort makes up approximately 80%, and abdominal pain up to 70%. 65% of patients present with nausea and vomiting, 38% complain of malaise and weight loss, and about 33% of patients have diarrhea or constipation (17).

If left untreated trichobezoars can lead to serious complications such as peritonitis, gastric or duodenal perforation, acute pancreatitis, obstructive jaundice, sub-phrenic abscess,

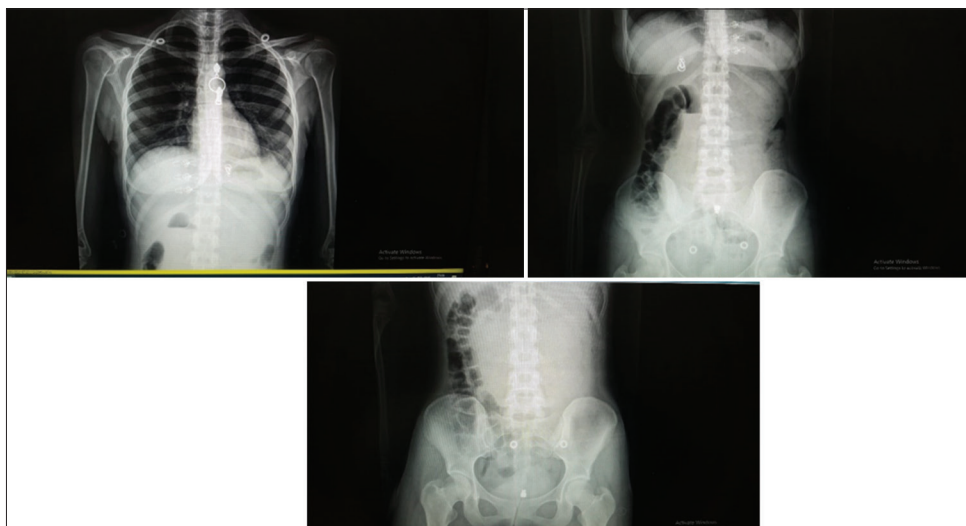


Figure 1. Plain X-ray Films of the Chest and The Abdomen

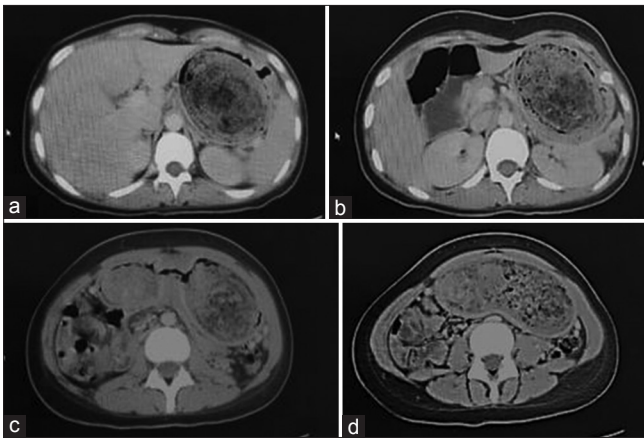


Figure 2. a, b, c, d Abdominal scan with contrast: the gastric lumen is occupied by heterogeneous material, with predominance of low density, mottled gas pattern extending to pylorus along with distention of second part of duodenum with air fluid level

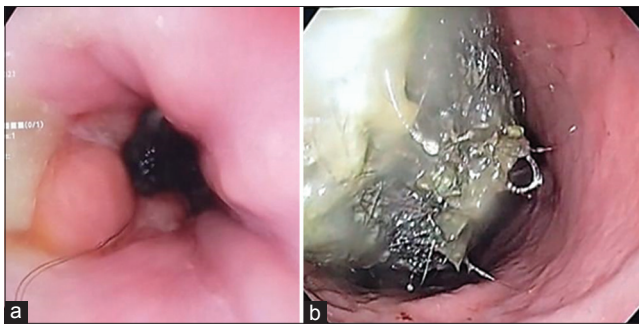


Figure 3. a Cardia, b Gastric lumen, Upper endoscopy demonstrating gastric-confined large trichobezoar

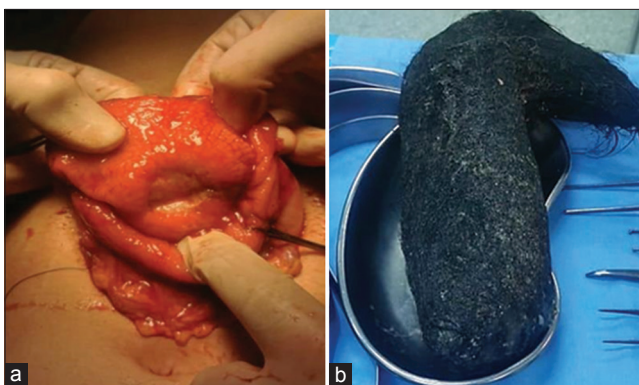

Figure 4. a Gastrostomy, b Specimen of extracted trichobezoar by gastrostomy: a hair cluster is observed adopting the gastric morphology

gastrointestinal hemorrhage, fistulas, intussusception, malabsorption, and iron deficiency anemia (13).

The diagnosis of a trichobezoar is made possible via imaging modalities. According to a study done by Ripolles et al (18) ultrasound, although might be the first line due to its accessibility and affordability, had many limitations including; diagnosing a bezoar located far from the surface of the abdomen, diagnosing multiple bezoars due to the impossibility of viewing the entire bowel loops, and distinguishing bezoars from ectopic lithiasis and/or fecal material. Further-

more, it has a low sensitivity in diagnosing gastric bezoars due to the fact that hair is highly echogenic, and the presence of trapped air bubbles and various acoustic reflections. (18)

Plain abdominal film can be used in diagnosing an obstruction but is of no benefit in obtaining further details (11)

On the other hand, computed tomography (CT) scan is more accurate in diagnosing one or multiple bezoars and defining their location. The presence of a well-defined oval heterogenous mass with interspersed air bubbles inside the lumen of the bowel is suggestive of a bezoar. If the bezoar was causing an obstruction, the bowel proximal to the mass would be dilated, while the bowel distal to it would be normal or collapsed. (18) Ct scans are more readily available, and less time consuming making them the preferable modality for our patient.

Upper gastrointestinal endoscopy is of importance due to its ability to tell different types of bezoars apart, which is important in deciding the treatment plan since phytobezoars, for instance, can be softened by enzymatic dissolution. While trichobezoars require removal via an anterior gastrotomy (19). In our case such a large trichobezoar could not have been removed via an upper endoscope.

A laparoscopic procedure would have been a preferred tool for its cosmetic benefits only. Otherwise, it has a low efficacy because it is complex, time-consuming, and it adds to the difficulty of inspecting and palpating the entire intestines looking for the presence of additional bezoars. Not to mention the fact that it will predispose the patient for more anesthetic complications.

CONCLUSION

Though trichobezoar is a rare entity in clinical practice, it is vital to be early diagnosed. This is important in order to avoid the accompanying complications which unfortunately may lead to death.

COMPETING INTERESTS

All authors declare no conflicts of interest in this paper.

REFERENCES

1. LaGrandeur W, Zukowski M. Large Trichobezoar in School-Aged Girl Presenting to the Emergency Department with Hematemesis. *J Emerg Med.* 2021 Dec;61[6]: e167-e169. doi: 10.1016/j.jemermed.2021.07.040. Epub 2021 Sep 24. PMID: 34565634.
2. Niță AF, Hill CJ, Lindley RM, Marven SS, Thomson MA. Human and Doll's Hair in a Gastric Trichobezoar, Endoscopic Retrieval Hazards. *J Pediatr Gastroenterol Nutr.* 2020 Aug;71[2]:163-170. doi: 10.1097/MPG.0000000000002779. PMID: 32404761.
3. Bashir EA, Samiullah, Sadiq MA, Yusuf O, Karim K. Rapunzel syndrome. *J Ayub Med Coll Abbottabad.* 2010 Oct-Dec;22[4]:218-20. PMID: 22455302.
4. Gorter RR, Kneepkens CM, Mattens EC, Aronson DC, Heij HA. Management of trichobezoar: case report and lit-

AQ2

- erature review. *Pediatr Surg Int.* 2010 May;26[5]:457-63. doi: 10.1007/s00383-010-2570-0. Epub 2010 Mar 6. PMID: 20213124; PMCID: PMC2856853.
5. Castrillón Peña EL, Espinosa Moreno MF, Barrios Torres JC, Forero Niño EE. Tricobezoar gastroduodenal en la edad escolar: Caso clínico [Gastroduodenal Trichobezoar in school age: Case report]. *Arch Argent Pediatr.* 2019 Jun 1;117[3]: e284-e287. Spanish. doi: 10.5546/aap.2019.e284. PMID: 31063318
 6. Ventura DE, Herbella FAM, Schettini ST, Delmonte C. Rapunzel syndrome with a fatal outcome in a neglected child. *J Pediatr Surg.* 2005;40:1665–1667. doi: 10.1016/j.jpedsurg.2005.06.038. [PubMed] [CrossRef] [Google Scholar]
 7. Mehta MH, Patel RV. Intussusception and intestinal perforations caused by multiple trichobezoars. *J Pediatr Surg.* 1992;27:1234–1235. doi: 10.1016/0022-3468[92]90797-B. [PubMed] [CrossRef] [Google Scholar]
 8. Schreiber H, Filston HC. Obstructive jaundice due to gastric trichobezoar. *J Pediatr Surg.* 1976;11:103–104. doi: 10.1016/0022-3468[76]90182-2. [PubMed] [CrossRef] [Google Scholar]
 9. Hossenbocus A, Colin-Jones DG. Trichobezoar, gastric polyposis, protein losing enteropathy and steatorrhea. *Gut.* 1973;14:130–132. doi: 10.1136/gut.14.9.730. [PMC free article] [PubMed] [CrossRef] [Google Scholar]
 10. Shawis RN, Doig CM. Gastric trichobezoar with transient pancreatitis. *Arch Dis Child.* 1984;59:994–995. doi: 10.1136/adc.59.10.994. [PMC free article] [PubMed] [CrossRef] [Google Scholar]
 11. O'sullivan, M.J., McGreal, G., Walsh, J.G. and Redmond, H.P., 2001. Trichobezoarbezoar. *Journal of the Royal Society of Medicine*, 94[2], pp.68-70.
 12. Gorter RR, Kneepkens CM, Mattens EC, Aronson DC, Heij HA. Management of trichobezoarbezoar: case report and literature review. *Pediatr Surg Int.* 2010 May;26[5]:457-63. doi: 10.1007/s00383-010-2570-0. Epub 2010 Mar 6. PMID: 20213124; PMCID: PMC2856853.
 13. Lyons, D., 2019. Large gastric trichobezoarbezoar causing failure to thrive and iron deficiency anaemia in an adolescent girl: a case report emphasising the imaging findings and review of the literature. *BJR| case reports*, 5[2], p.20180080
 14. Sood, A.K., Bahl, L., Kaushal, R.K., Sharma, V. and Grover, N., 2000. Childhood trichobezoarbezoar. *The Indian Journal of Pediatrics*, 67[5], pp.390-391.
 15. Pace, A.M. and Fearn, C., 2003. Trichobezoarbezoar in a 13 year old male: a case report and review of literature.
 16. Hamidi, H., Muhammadi, M., Saberi, B., & Sarwari, M. A. [2016]. A rare clinic entity: Huge trichobezoarbezoar. *International journal of surgery case reports*, 28, 127–130.
 17. Ersoy, Y.E., Ayan, F., Ayan, F. and Ersan, Y., 2009. Gastro-intestinal bezoars: thirty-five years experience. *Acta Chirurgica Belgica*, 109[2], pp.198-203.
 18. Ripollés T, García-Aguayo J, Martínez MJ, Gil P. Gastrointestinal bezoars: sonographic and CT characteristics. *AJR Am J Roentgenol.* 2001 Jul;177[1]:65-9. doi: 10.2214/ajr.177.1.1770065. PMID: 11418400.
 19. De Backer, Antoine; Van Nooten, Vera*; Vandenplas, Yvan† Huge Gastric Trichobezoar in a 10-Year-Old Girl: Case Report With Emphasis on Endoscopy in Diagnosis and Therapy, *Journal of Pediatric Gastroenterology & Nutrition*: May 1999 - Volume 28 - Issue 5 - p 513-515
 20. Al-Janabi, I.S., Al-Sharbaty, M.A., Al-Sharbaty, M.M. et al. Unusual trichobezoar of the stomach and the intestine: a case report. *J Med Case Reports* 8, 79 [2014]. <https://doi.org/10.1186/1752-1947-8-79>

Author Queies???

AQ2: Kindly cite reference 4 and 8 in the text part and also chronological order