

Case Report

20 Years' Experience in Treating Kienbock's Disease: About 15 Cases and Review of Literature

Badr Chalouah^{1*}, Benchakroun Mohamed²; El mokhtari Kamal¹; Bennis azzelarab²; Zaddoug omar²; Zine ali²; Tanane mansour²; Bouabid salim³

¹Resident in orthopedics-traumatology surgery, Department of orthopedics-traumatology I, Mohamed V military hospital, BP 10 100 RABAT, MOROCCO

²Professor in orthopedics-traumatology surgery, Department of orthopedics-traumatology I, Mohamed V military hospital, BP 10 100 RABAT, MOROCCO

³Professor, Head department of orthopedics-traumatology I, Mohamed V military hospital, BP 10100; RABAT, MOROCCO

Corresponding Author: Badr Chalouah, E-mail: chalouahbadr@gmail.com

ARTICLE INFO

Article history

Received: January 20, 2022

Accepted: March 19, 2022

Published: April 30, 2022

Volume: 10 Issue: 2

Conflicts of interest: None.

Funding: None.

Keywords:

Kienbock,
Osteonecrosis,
Lunate,
Avascular,
Classification

ABSTRACT

Kienböck's disease is a rare condition. It affects young adults who are mostly manual workers. Radiology allows diagnosis and classification of the disease using the Lichtman classification which will guide the therapeutic strategy. The aim of the present work is to review the clinical data, recent advances in assessment methods (MRI and arthroscopy) and our therapeutic results compared to the literature. **Material and methods:** This is a retrospective study of fifteen cases of Kienböck's disease, collected in the Traumatology-Orthopaedics Department I of the Mohamed V Military Hospital in Rabat, Morocco, over a 20 years period, from 2001 to 2020. This study included 10 men and 5 women, with an average age of 29 years. All of our patients underwent plain radiographs that allowed diagnosis and staging. Only 6 patients benefited from MR imaging and none of them had cartilage arthroscopic assessment. Radial shortening osteotomy were performed for 14 patients and lunate decompression by forage for one patient with good results in 53% and 14% of poor results. **Discussion:** Comparing the results of our study with those of the literature, we found concordance regarding clinical, radiological and therapeutic methods. However, this study has shown insufficient use of MRI for viability evaluation of the lunate and cartilage arthroscopic assessment, due in first place to their high cost for developing countries as ours. Thus, treatment choices weren't accurate enough, which explains our 47% poor to fair results. **Conclusion:** Kienböck's disease is a rare condition that should be early diagnosed with accurate staging using recent advances in assessment methods which allows proper treatment choices to prevent its evolution toward total destruction of the wrist. However, patient's desires and needs, surgeon's experience and capabilities of their facilities precondition the final decision.

INTRODUCTION

Even the avascular osteonecrosis of the lunate was describe over 100 years ago by a Viennese radiologist, Robert kienbock's disease aetiology still unknown and controversial (1). However, the knowledge about osteomalacia of the lunate describes risk factors that increases its incidence. The anatomical risk factors include the shape of the lunate and distal radius, ulnar variance, and the coverage of lunate by radius, the blood supply, the excessive intraosseous pressure and the venous stasis (2). Personal factors include age and gender, the associated diseases, the trauma-related factors, the social and environmental factors, and the association with osteonecrosis of other carpal bones (2). Forced manual labor is now described more as factor aggravating a pre-existing condition than a risk factor (3).

Kienbock's disease is classified as rare with a peak incidence in male patients aged 20-40 years. One hand is usually affected (4). The natural history of kienbock's disease is described as the progression of clinical findings and seri-

al radiological changes. The clinical presentation associate dorsal tenderness and swelling, decreased range of motion (ROM) of the wrist and reduced grip strength (2, 5). Proper classification of the kienbock's disease is crucial in choosing the right treatment. Thus, the Lichtman osseous scale is the most common radiological classification (6). However, Schmitt's vascularisation MRI evaluation (7) and Bain's cartilage arthroscopic assessment (8) are important in proper staging of the disease. Treatment of kienbock's disease varies from conservative options to surgical procedures, which can make proper choice of treatment difficult (9).

MATERIALS AND METHODS

We have conducted a retrospective study of 15 cases of kienbock's disease at the orthopaedics and trauma department I in Mohammed V military hospital of Rabat, Morocco, over a period of 20 years (2001-2020).

Patient's clinical and radiological presentation were extracted from our medical records. Thus, we searched for patient's age, gender, medical history, profession and clinical symptoms. All our patients underwent standard posteroanterior and lateral radiographs of both wrists in unloaded conditions with the shoulder abducted at 90°, the elbow flexed at 90° and forearm on the X-ray table, to diagnose and follow the progression of the kienbock's disease using the Lichtman classification. Also, we measured the diameter and height of the lunate, the lunate tilting angle, the lunate uncovering index, the lunate fossa inclination, the radial inclination, the ulnar variance, the radio-lunar angle and the scapho-lunar angle (figure 1). MR imaging with gadolinium perfusion were performed for 6 patients (40%) and no arthroscopic assessment were conducted.

Surgery were performed for all our patients with lunate unloading procedure by radial shortening osteotomy for 14 patients (93%) and lunate decompression by forage with bone grafting for 1 patients. Average follow-up for 3 years and 3 months post-operatively with clinical assessment of pain, ROM of the wrist, grip strength and radiological evaluation using Lichtman classification.

RESULTS

The average age of our patients were 29 years with extreme age of 21 and 47 years, 66% were males. The dominant wrist were affected in 53% of the cases, only 33% reported a traumatic history and 12 patients (80%) have a repetitive manual work. All our patients presented dorsal stiffness with reduced ROM of the wrist and decreased grip strength evolving for a year in average (from few months to 3 years).

According to Lichtman classification, 54% of our patients were stage III (5 IIIA, 2 IIIB and 1 IIIC), 33% Lichtman II and 14% Lichtman I. MRI shown low T1-weighted FSE signal in all 6 patients(40%) with variable T2-weighted FSE signal, comforting diagnosis of kienbock's disease specially for Lichtman I patients (fig.2).

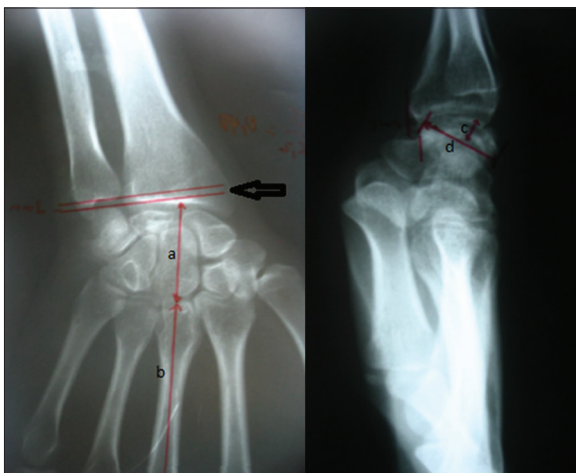


Figure 1. A-P and lateral X-rays of the wrist showing kienbock's disease stage IIIb with measurement of: Ulnar variance: negative (black arrow) a/b: (height of carpe/height of central metacarpal) shows collapse of central column c: height of collapsed lunate d: diameter of lunate

All patients underwent surgery, 93% had a lunate unloading procedure by radial shortening osteotomy (fig.3), using Henry's approach to distal forearm and internal fixation by T-plate (fig.4), which protect the lunate and set the stage for spontaneous revascularization. In one case, we performed lunate forage by drilling the lunate to decompress venous hypertension in conjunction with cancellous bone grafting. Protective cast immobilisation of upper arm in functional

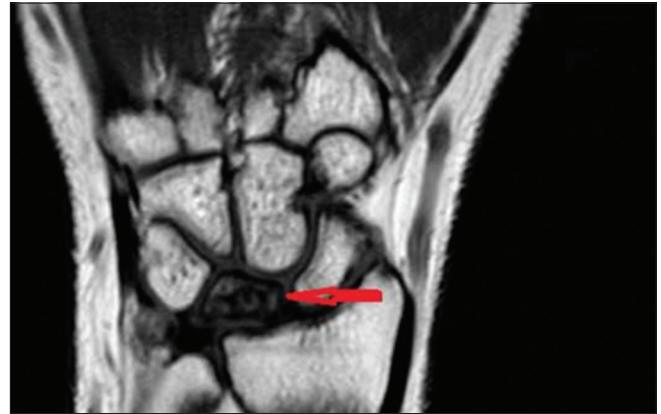


Figure 2. MR image showing low T1 signal of the lunate

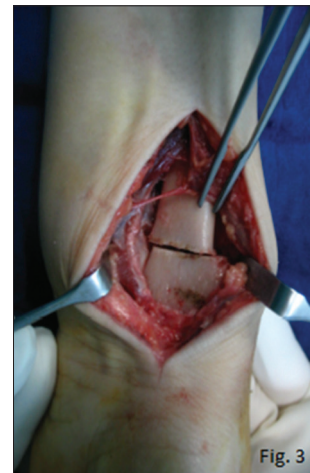

Figure 3. Per-operative image showing radial shortening osteotomy

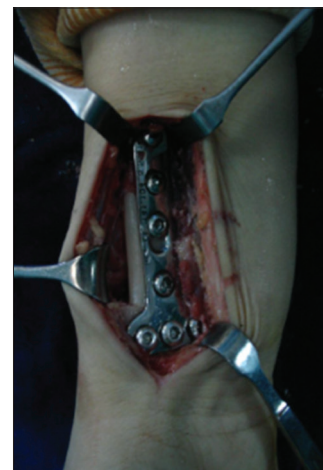


Figure 4. Per-operative image showing internal fixation by T-plate

position was applied for patients with radial osteotomy with elbow release after 6 weeks postoperatively. All patients underwent proper rehabilitation in a specialized centre.

The average follow-up in our study was for 3 years and 3 months with extremes between 2 and 5 years. According to green and O'Brien modified by Cooney score for functional assessment of the wrist, our results were good in 53%, fair in 33% and poor in 14%. However, all patients showed stabilization of radiological findings according to Lichtman classification (Fig. 5 and 6).

DISCUSSION

The avascular osteonecrosis of the lunate is a rare disease and its prevalence is about 7 per 100000 (10, 11). It shows, as in our study, a male predominance with a peak incidence between 20-40 years (12). However, paediatric and elderly forms has been reported with a better prognosis than the typically 20-40 years patients (2, 13 and 14). Usually, one hand is affected and only 4% of cases are bilateral (15). All our patients had one wrist affected and it were the dominant one in 53%. 80% of our patients were hand workers (carpenter, truck driver, housewife, seamstress...) which suggest that repetitive manual labor has a role in the etiopathogeny of

kienbock's disease. Recent studies suggests that manual labor is more as an aggravating factor of an established disease than a risk factor (3).

Typically, kienbock's disease is suggested in case of dorsal tenderness of the wrist with swelling (Fig. 7), reduced ROM and grip strength (Fig.8), with or without a traumatic history evolving since a few months as reported by all our cases. Plain radiographs are used to confirm diagnosis and follow progression of kienbock's disease using Lichtman classification (16). Furthermore, Schmitt et al. demonstrated how MRI especially with gadolinium perfusion is valuable in evaluating viability of bone marrow and amalgam their findings in a MRI classification (7). Also, arthroscopic articular assessment reported by Bain et al. has proven its importance in influencing treatment decisions in patients with kienbock's disease (8). They reported that plain radiographs often underestimate the severity of articular changes since 82% of cases had at least one non-functional articulation (8). Thus, an articular-based approach to treatment was developed based on the functional articular surfaces (8, 17). In our study, only 6 patients benefited from MRI with gadolinium perfusion and unfortunately none of them had arthroscopic assessment due mostly to their socioeconomically status. Thus, we consider that although Schmitt's and Bain's findings are very valuable for understanding and treating kienbock's disease, they are not practical in low income countries as ours, in which Lichtman classification remain the

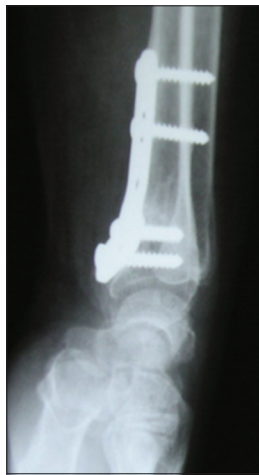

Figure 5. Follow-up X-rays showing stabilization of kienbock's disease (brown arrow)

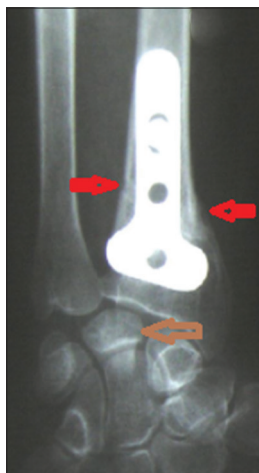

Figure 6. Bone consolidation of radial osteotomy (red arrows)

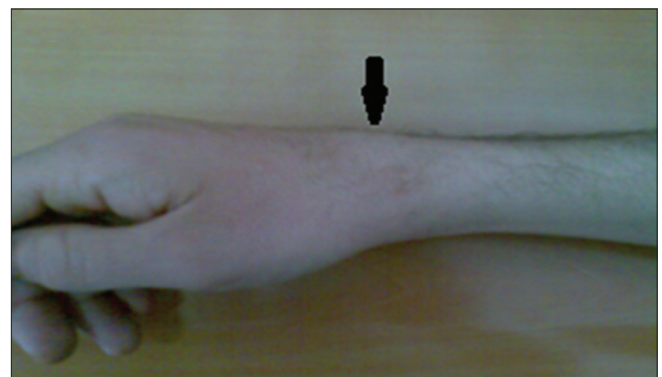

Figure 7. Image of dorsal swelling of the wrist (black arrow)



Figure 8. Image of reduced ROM of the wrist

gold standard for staging this disease due to its simplicity and accessibility.

The management of Kienbock's disease should consider a several important concepts that determine the outcome of the patient such as patient's age, the lunate revascularization potential, the pathoanatomical aspects of the lunate disease and its secondary effects on the wrist (14). The age at presentations is important since paediatric (<15 years) and elderly (>70 years) patients has better prognosis and respond very well to non-operative treatments in most cases (18).

For patients, 21 to 69 years, it is important to consider the lunate stage. Thus, if the lunate is intact (Lichtman stage 0, I and II; Schmitt stage A and Bain grade 0), treatment aims to protect the vulnerable lunate, first by non-operative management as short arm cast for at least 3 months (14). For patients who fail non-operative management, lunate unloading procedures are considered, such radial shortening osteotomy (RSO) for patients with negative ulnar variance. For patients with neutral or positive ulnar variance, a capitate shortening osteotomy should be performed. Lunate decompression (LD) by forage is also an option at this stage (14). In case of the lunate is compromised (Lichtman stage IIIA, Schmitt stage B and Bain grade 1), a reconstruction of the proximal lunate with vascularized medial femoral trochlear graft (MFTG) is indicated (19). However, this is a demanding procedure and other treatments are needed such radioscapholunate fusion or scaphocapitate fusion (20). If the lunate is not reconstructable (Lichtman stage IIIC, Schmitt stage C and Bain grade 2b), then only lunate salvage is available by either lunate replacement by an implant (silicone (17, 21), autogenous tendon or pyrocarbon implants (22, 23)) but often with poor results (24), or by proximal row carpectomy, a time tested technique (14). In our department, we performed RSO for most of our patients (93%) and we did not respect faithfully this concept of lunate stage in our approach to treat our patients, which could explain our 47% poor to fair results.

Also, it is important to consider the side effects of the lunate collapse on the wrist, which include degeneration and collapse of the central column at the radiolunate and mid-carpal articulations with or without carpal collapse by degenerated radial column (radioscaphoid angle > 60°) (25, 26). In this case, wrist stabilization by scaphocapitate fusion is the recommended procedure (14). Finally, if the wrist is not reconstructable (Lichtman stage IV, Schmitt stage C and Bain grade 2-4), only wrist salvage procedures could be performed as wrist fusion or wrist arthroplasty (14).

CONCLUSION

The avascular osteonecrosis of the lunate is a rare disease that still holds many unknown concepts of its etiopathogeny. However, thanks to the osseous-Lichtman (16), vascular-Schmitt (7), cartilage-Bain (8) most important findings, a better and more complete algorithm for the treatment of Kienbock's disease has been established (14). However, the needs and desires of each patient, their lifestyle and demands on the wrist, surgeon's experience and the capabilities of their facilities remain a significant factors in addressing such condition as Kienbock's disease.

REFERENCES

- Arora, R.; Lutz, M.; Deml, C.; Krappinger, D.; Zimmermann, R.; Gabl, M. Long-term subjective and radiological outcome after reconstruction of Kienböck's disease stage 3 treated by a free vascularized iliac bone graft. *J. Hand Surg. Am.* **2008**, *33*, 175–181. [CrossRef] [PubMed]
- Fontaine, C. Kienböck's disease. *Chir. Main* **2015**, *34*, 4–17. [CrossRef] [PubMed]
- Lluch, A.; Garcia-Elias, M. Etiology of Kienböck disease. *Tech. Hand Up. Extrem. Surg.* **2011**, *15*, 33–37. [CrossRef] [PubMed]
- H. Evrard, C. Guillaume, F. Hoet, H. Koenig, F. Van Innis, La maladie du semi-lunaire, *Annales de Chirurgie de la Main*, Volume 1, Issue 3, 1982, Pages 280-283.
- Beckenbaugh RD, Shives TC, Dobyns JH, Linscheid RL. Kienböck's disease: the natural history of Kienböck's disease and consideration of lunate fractures. *Clin Orthop Relat Res* 1980;1(149):98–106.
- Beredjikian, P.K. Kienböck's disease. *J. Hand Surg. Am.* **2009**, *34*, 167–175. [CrossRef]
- Schmitt, R.; Heinze, A.; Fellner, F.; Obletter, N.; Strühn, R.; Bautz, W. Imaging and staging of
- Bain, G.I.; Durrant, A. An articular-based approach to Kienbock avascular necrosis of the lunate. *Tech. Hand Up. Extrem. Surg.* 2011, *15*, 41–47. [CrossRef]
- Alsanawi, H. Surgical interventions for Kienbock's disease: An update. *J. Health Spec.* **2017**, *5*, 12. [CrossRef]
- Facca, S.; Gondrand, I.; Naito, K.; Lequent, T.; Nonnenmacher, J.; Liverneaux, P. Graner's procedure in Kienböck disease: A series of four cases with 25 years of follow-up. *Chir. Main* **2013**, *32*, 305–309. [CrossRef] [PubMed]
- Van Leeuwen, W.F.; Janssen, S.J.; ter Meulen, D.P.; Ring, D. What Is the Radiographic Prevalence of Incidental Kienböck Disease? *Clin. Orthop. Relat. Res.* **2016**, *474*, 808–813. [CrossRef] [PubMed]
- White, C.; Benhaim, P.; Plotkin, B. Treatments for Kienböck disease: What the radiologist needs to know. *Skeletal Radiol.* 2016, *45*, 531–540. [CrossRef] [PubMed]
- Lichtman DM, Degnan GG. Staging and its use in the determination of treatment modalities for Kienböck's disease. *Hand Clin* 1993; 9(3):409–416.
- Lichtman DM, Pientka WF 2nd, Bain GI. Erratum: Addendum: Kienböck Disease: A New Algorithm for the 21st Century. *Journal of Wrist Surgery.* 2017 Feb;6(1):e1-e2. DOI: 10.1055/s-0037-1604137. PMID: 31305794; PMCID: PMC5599258.
- Chojnowski, K., Opielka, M., Piotrowicz, M., Sobocki, B. K., Napora, J., Dąbrowski, F., & Mazurek, T. (2022). Recent Advances in Assessment and Treatment in Kienböck's Disease. *Journal of Clinical Medicine*, *11*(3), 664.
- Lichtman DM, Mack GR, MacDonald RI, Gunther SF, Wilson JN. Kienböck's disease: the role of silicone replacement arthroplasty. *J Bone Joint Surg Am* 1977;59(7):899–908.
- Bain GI, Begg M. Arthroscopic assessment and classification of Kienbock's disease. *Tech Hand Up Extrem Surg* 2006;10(1):8–13.

18. Irisarri C, Kalb K, Ribak S. Infantile and juvenile lunatomalacia. *J Hand Surg Eur Vol* 2010;35(7):544–548.
19. Higgins JP, Bürger HK. Osteochondral flaps from the distal femur: expanding applications, harvest sites, and indications. *J Reconstr Microsurg* 2014;30(7):483–490.
20. Bürger HK, Windhofer C, Gaggl AJ, Higgins JP. Vascularized medial femoral trochlea osteochondral flap reconstruction of proximal pole scaphoid nonunions. *J Hand Surg Am* 2013;38(4): 690–700.
21. Roca J, Beltran JE, Fairen MF, Alvarez A. Treatment of Kienböck's disease using a silicone rubber implant. *J Bone Joint Surg Am* 1976; 58(3):373–376.
22. Werthel JD, Hoang DV, Boyer P, Dallaudière B, Massin P, Loriaut P. Treatment of Kienböck's disease using a pyrocarbon implant: case report [in French]. *Chir Main* 2014;33(6):404–409.
23. Bellemère P, Maes-Clavier C, Loubersac T, Gaisne E, Kerjean Y, Collon S. Pyrocarbon interposition wrist arthroplasty in the treatment of failed wrist procedures. *J Wrist Surg* 2012;1(1):31–38.
24. Saffar P. Vascularized pisiform transfer in place of lunatum for Kienböck's disease [in French]. *Chir Main* 2010;29(Suppl 1): S112–S118.
25. Boyer JS, Adams B. Distal radius hemiarthroplasty combined with proximal row carpectomy: case report. *Iowa Orthop J* 2010; 30:168–173.
26. Gelberman RH, Bauman TD, Menon J, Akeson WH. The vascularity of the lunate bone and Kienböck's disease. *J Hand Surg Am* 1980; 5(3):272–278.