

## Case Report

### Rare Case of a Doubly Complicated Clavicle Fracture in a Cyclist

Rhita Salah\*, Naoufal El Ghouf, Kamal El Mokhtari, Azzelarab Bennis, Omar Zaddoug, Mohamed Benchakroun, Ali Zine, Mansour Tanane, Salim Bouabid

*Orthopedic Surgery and Traumatology, Department of Orthopedic Surgery and Traumatology, Military Hospital Mohammed V*

**Corresponding Author:** Rhita Salah, E-mail: rhita.salah@gmail.com

#### ARTICLE INFO

##### Article history

Received: January 14, 2022

Accepted: March 25, 2022

Published: April 30, 2022

Volume: 10 Issue: 2

Conflicts of interest: None.

Funding: None.

#### Keywords:

Clavicle,

Cyclist,

Fracture,

Pneumothorax,

Deep vein thrombosis

#### ABSTRACT

Fractures of the clavicle represent 2.6 to 5% of all fractures. Respiratory and vascular-nerve complications of isolated clavicle fractures are rare. We report the case of a 29-year-old cyclist who presented a fracture of the right clavicle following a sport accident, complicated by both pneumothorax and deep vein thrombosis of axillary vein. Patient underwent thoracic drainage and curative anticoagulation followed by internal osteosynthesis of the clavicle as soon as he was stabilized on respiratory level. At the last check-up, the clavicle healed and no recurrence of pneumothorax nor deep vein thrombosis was noted.

#### INTRODUCTION

Clavicle fractures represent 2.6 to 5% of all fractures. Fractures of the middle third are the most frequent (1). They usually occur in young adults following a sport or road traffic accidents (2). However, acute complications of isolated clavicle fractures are rare. Pneumothorax is seen in 3% of cases and deep vein thrombosis in less than 1% (3). We report the case of a 29-year-old cyclist presenting a fracture of the right clavicle complicated simultaneously by pneumothorax and deep vein thrombosis of the axillary vein following a sports accident.

#### CASE REPORT

We report the case of a 29-year-old cyclist, without medical history, who presented with pain of the right shoulder girdle following a traumatic fall onto the shoulder.

Patient was admitted to the emergency room (2H after the trauma). He was conscious, hemodynamically stable with tachypnea at 25 breaths per minute and an oxygen saturation at 94% under room air. Pulmonary percussion and auscultation were normal.

Locomotor examination found a swelling of the right clavicular region without skin opening. All pulses were palpable. Nerve examination was unremarkable.

Chest X-ray revealed a low abundance right anterior pneumothorax (Figure 1).

Right shoulder X-ray showed a comminuted fracture of the middle third of the right clavicle (Figure 2).

Chest CT scan confirmed the presence of pneumothorax and ruled out rib fracture or other associated lesions (Fracture 3).

Patient received initially oxygen therapy with thoracic drainage.

Twenty-four hours later, he presented diffuse pain in right upper limb with increase in volume, heat and pain during mobilization (Figure 4).

Axillary, humeral, radial and ulnar pulses were present and symmetrical. Nerve examination found no sensory-motor deficit. Axillary vein was incompressible on Doppler ultrasound with hypoechoic homogeneous endoluminal material, suggesting a thrombosis.

Heparin infusion was then started, and as soon as the patient was stabilized on the respiratory level, we removed the chest drain and performed clavicle fixation using a plate by direct approach, under general anesthesia and in beach chair position (Figure 5).

The immediate post-operative period was unremarkable. The patient was discharged on antithrombotic drug. At the last

18 months check-up, the clavicle healed and no recurrence of pneumothorax nor deep vein thrombosis was noted.

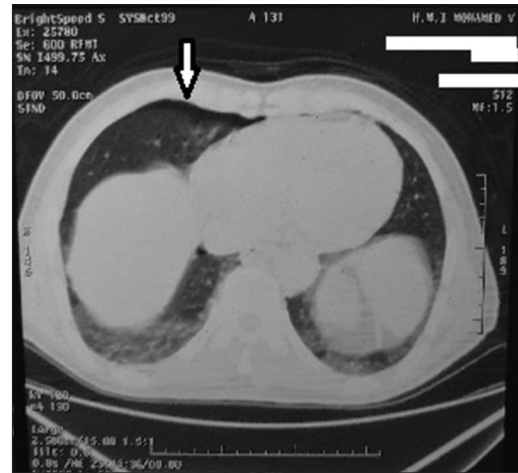**DISCUSSION**

Fractures of the clavicle can be lethal considering the proximity of vasculo-nervous elements and the apex of the lung to the clavicle. Only a few cases of isolated clavicle fractures complicated by pneumothorax, vascular or brachial plexus injuries have been reported in the literature so far. Their incidences are respectively 3%, 1% and less than 1% (3).

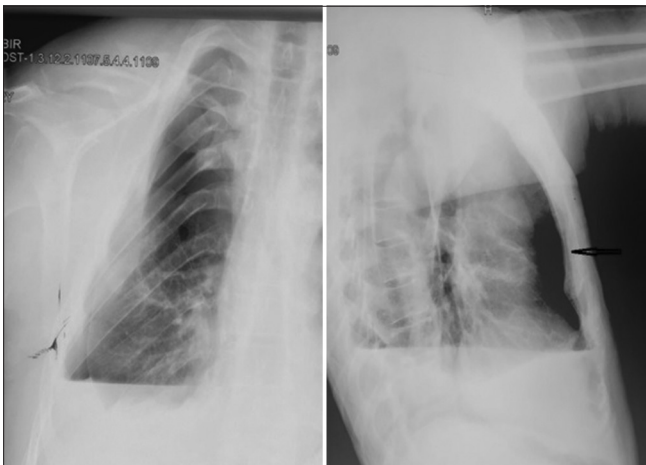
Deep vein thrombosis (DVT) of the upper limb is very rare, representing only 2 to 4% of all DVTs (4). They usually occur during a central venous catheter placement, by tumor compression or as part of a general pathology such as thrombophilia, paraneoplastic syndrome or systemic disease. They uncommonly occur following a fracture of the upper limb (5).

Painful swelling of the hand with extension to the forearm and the arm is the main symptom of DVT. Venous Doppler ultrasound confirms the diagnosis and specifies the extent of the thrombus. Treatment is based on curative anticoagulation associated to the treatment of the cause (6).

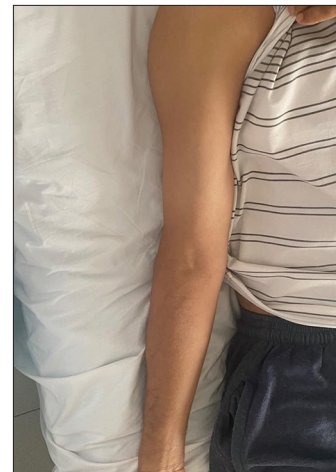The apex of the lung lies behind and above the medial third of the clavicle which explains the risk of pneumothorax and hemopneumothorax, most often due to a pleural breach (7).



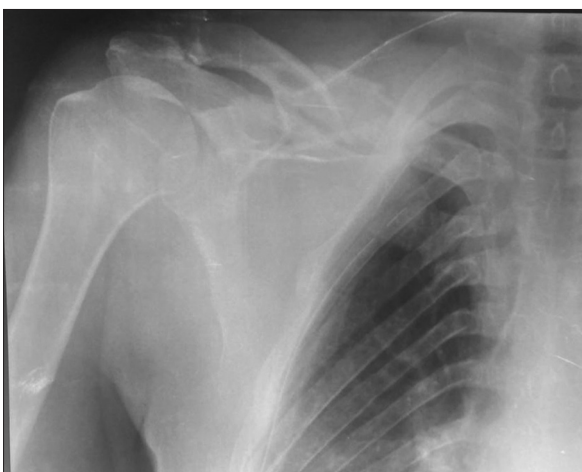**Figure 3.** Chest CT scan showing a low abundance right anterior pneumothorax



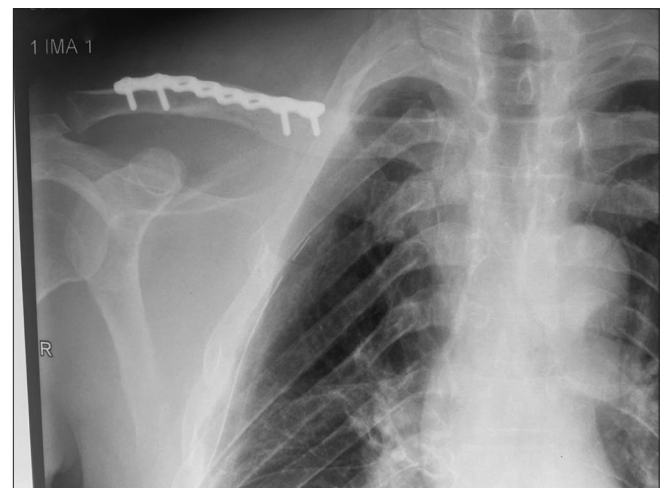
**Figure 1.** Chest x-ray showing a low abundance right anterior pneumothorax



**Figure 4.** Clinical image of the upper right limb increased in size



**Figure 2.** Right shoulder x-ray showing a comminuted fracture of the middle third of the right clavicle



**Figure 5.** Right shoulder x-ray after osteosynthesis of the clavicle using a plate

Pneumothorax manifests with sudden post-traumatic dyspnea or even respiratory distress. Oxygen therapy with chest drainage are thus necessary (8).

In a series of 690 clavicle fractures, 3% were complicated by pneumothorax according to Rowe (9). Landine et al. didn't report any case of pneumothorax in their series of 172 patients (10). This confirms the rarity of this complication, however, any patient with a clavicle fracture should have their respiratory status meticulously evaluated.

Clavicle fractures usually heal with routine immobilization. Nonetheless, surgery can be useful or even mandatory in acute cases of comminuted or with large displacement fractures, shortening of more than 20mm, skin tenting, vasculo-nervous or respiratory complications (1).

## CONCLUSION

Despite their benignity and frequency, clavicle fractures can have dramatic evolution when complicated by pneumothorax or vasculo-nervous lesions. This suggests the importance of careful clinical examination with radiological confirmation in the slightest doubt. Chest-rays should be in our opinion, part of the standard radiological assessment of a clavicle fracture, in order to detect a pneumothorax.

## REFERENCES

1. BOUILLET, B., MOREEL, P., et DESCAMPS, S. Prise en charge des fractures récentes de la clavicule. *Journal de traumatologie du sport*, 2009, vol. 26, no 1, p. 24-31.
2. Robinson, C. M. (1998). Fractures of the clavicle in the adult: epidemiology and classification. *The Journal of bone and joint surgery. British volume*, 80(3), 476-484.
3. Meeks, R. J., & Riebel, G. D. (1991). Isolated clavicle fracture with associated pneumothorax: a case report. *The American journal of emergency medicine*, 9(6), 555-556.
4. Prescott, S. M., & Tikoff, G. E. R. A. S. I. M. (1979). Deep venous thrombosis of the upper extremity: a reappraisal. *Circulation*, 59(2), 350-355.
5. Manjaoui, J., Benchbba, D., Jaafar, A., Sirbou, R., Belyamani, L., & Dimou, M. (2011). Thrombose veineuse profonde du membre supérieur compliquant une fracture de la clavicule. À propos d'un cas. *Journal de traumatologie du sport*, 28(1), 41-43.
6. Heron, E. (2009). Thromboses veineuses profondes des membres supérieurs. *Encycl Med Chir Pneumologie* 6-024-B-27.
7. Hani, R., Ennaciri, B., Jeddi, I., Bardouni, A. E., Mahfoud, M., & Berrada, M. S. (2015). Pneumothorax complicating isolated clavicle fracture. *Pan African Medical Journal*, 21(1).
8. Feriani, N., Ben Ghezala, H., & Snouda, S. (2016). Pneumothorax caused by an isolated midshaft clavicle fracture. *Case reports in emergency medicine*, 2016.
9. Rowe, C. R. (1968). 4 An Atlas of Anatomy and Treatment of Midclavicular Fractures. *Clinical Orthopaedics and Related Research (1976-2007)*, 58, 29-42.
10. Landine, J., McGraw, R., & Pickett, W. (2001). Clinical diagnosis of clavicle fractures: a pilot study. *Canadian Journal of Emergency Medicine*, 3(2), 95-98.