

**Case Report****Male Breast Cancer After a 20 Years of Treated Testicular Cancer, A Case Report**Mohammad Al-Share<sup>1</sup>, Mohammad Abu Jeyyab<sup>2</sup><sup>1</sup>FEBS Mutah University, Amman, Jordan<sup>2</sup>MBBS Mutah University, Amman, Jordan**Corresponding Author:** Mohammad Al-Share, E-mail: alshare079@gmail.com**ARTICLE INFO***Article history*

Received: January 03, 2022

Accepted: March 12, 2022

Published: April 30, 2022

Volume: 10 Issue: 2

Conflicts of interest: None.

Funding: None.

**Key words:**

Breast cancer,

Testicular cancer,

Mass,

lump,

Case report

**ABSTRACT**

Breast cancer in male gender is rare with an incidence of 1 % of all breast cancers. There are many theories and risk factors that play a role in the development of breast cancer among males. The development of a second primary cancer is also rare. Herein we have a case of a male breast cancer that devolved after a 20 years of treated testicular cancer. There are many risk factors that should be studied to know correlation between the two diseases. In this case report we will show the presentation of the patient, discuss the risk factors and put our treatment plan.

**INTRODUCTION**

Patients with cured testicular cancer have a higher incidence to develop neoplasms than other normal subjects (1). Many factors play a role in the development of a second primary cancer among these patients such as the long-term complications of radiotherapy, and the effect of unexplained past hormonal therapy (2). Male Breast Cancer (MBC) is a rare disease accounting for 1% of all breast cancer cases (3). The risk factors of MBC include family history of breast cancer especially with the ductal carcinoma in situ type, disrupted hormonal status with elevated estrogen and low male androgens, age above 60 years and black ethnicity (2). The case report presents a case of MBC for a 59-year-old male with a history of orchietomy surgery and radiotherapy for treatment of testicular cancer.

**CASE PRESENTATION**

A 59-year-old male presented to the office complaining of a painful lump in his right breast. The patient noticed skin changes three months prior pain. The lump measured 15×20-mm and was firm and mildly tender (picture 1) The patient stated that the lump had grown in the past three months. The patient has a history of orchietomy surgery and radiother-

apy for treatment of testicular cancer. The patient also had family history of the first degree with a cured testicular cancer.

**CHEST ABDOMEN PELVIS CT SCAN**

The CT chest-abdomen-pelvis with oral and IV contrast showed a right breast enhancing soft tissue lesion measuring about 1.6 x 2.3 cm with multiple right axillary lymph nodes; the largest measures about 1.3 cm in short axis for correlation with ultrasound and mammogram finding. Multiple left axillary lymph nodes were noted the largest measures about 0.9 cm short axis. Multiple sub centimeter mediastinal lymph nodes were noted. Multiple bilateral pulmonary nodules were noted in the largest seen posterior segment of the right lower lobe measuring about 1 x 1.3 cm mostly represent secondary deposits. No pleural effusion or pneumothorax was seen. Right liver lobe measured about 17.5 cm with evidence of 2 small hypodense lesion too small to be specified and could represent secondary deposits for follow-up. About 0.9 cm splenule was noted Spleen. Both adrenals, pancreas and both kidneys appeared unremarkable apart from bilateral renal cortical cysts the largest seen on the left side measuring about 2 x 2 cm. Multiple sub centimeter para-aortic and mesenteric lymph nodes were noted. No ascites was seen. Foci

of calcification was noted in the prostate centrally. Left-sided inguinal hernia with internal soft tissue contents for correlation with ultrasound findings. Left femoral neck lytic lesion with sclerotic margin right iliac bone sclerotic lesion for correlation with bone scan.

## LABORATORY FINDINGS

The level of free testosterone was 9.9L pmol/L (12.49-89.17), Estradiol was 91.,542 pmol/L (28-156), Progesterone was 0.606L nmol/L (0.7-4.3), and total testosterone was 3.293L nmol/L (9.9-27.8)

## HISTOPATHOLOGY

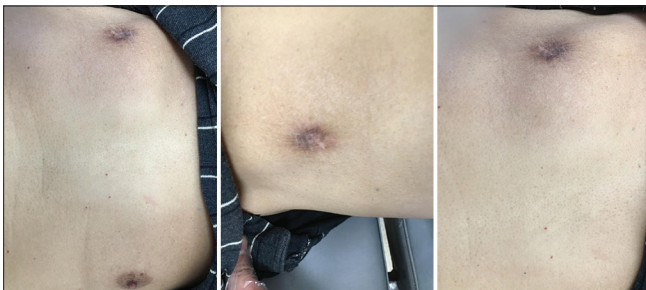
Sections showed multiple small needle core biopsies, two fragments of them showing sheets foci of sheet of invasive mammary carcinoma and revealed positive E.cadherin, positive Her2neu negative (score (+1))

supplementary report: ER: positive score:5+2=7/8  
PR: positive score:4+2=6/8 KI67:more than 30%.

## DISCUSSION

Recently, it has been noticed that the survival outcome among male patients diagnosed with breast cancer is worse than female patients with breast cancer. In that, the 5-year survival rate for male patients was lower than that for female patients (82.8% vs. 88.5%). After taking into account the other factors, the risk of mortality in men with breast cancer was 43% higher than that in women during the follow-up period (4). Therefore, males who present with any symptoms that might suggest breast neoplasms should be taken seriously and thoroughly investigated.

Many factors contribute to the high mortality of male breast cancer patients; these include socioeconomic factors, mass



**Picture 1.** Male breast cancer for a 59-year-old male with a history of orchicectomy surgery and radiotherapy for treatment of testicular cancer

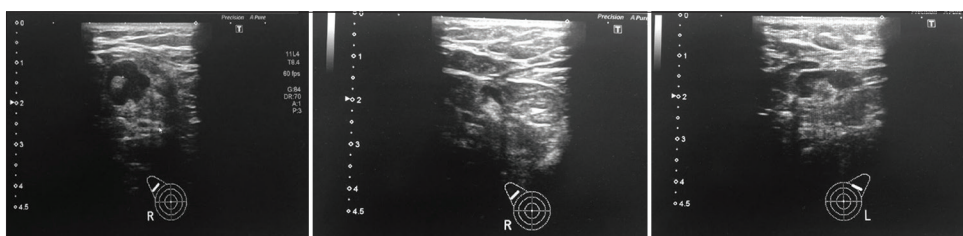
characteristics, stage of cancer and high Carlson- Dayo score. When it comes to management of malignant breast neoplasms in males, surgical intervention was the most effective modality, radiation, chemotherapy, and hormonal therapy comes next respectively. Additionally, Patients with positive ER or PR histo-immunological study clearly showed to have better survival. In order to decrease the mortality risk it is ultimately significant to determine socioeconomic factors, identify biomarkers, and choose the appropriate treatment means (5).

In addition, it was noticed that there is an increased risk of developing a secondary malignancy wither it was breast or non-breast in females with breast cancer have an, similarly this risk is applicable to male breast cancer patients (6). Age, obesity, consumption of alcohol consumption, family history, Klinefelter's syndrome, testicular disease, benign breast diseases, chest wall irradiation, liver cirrhosis, and hormonal treatment have been involved as risk factors in male breast carcinogenesis (7).

Genetically, factors include mutations of *AR* gene, *CYP17* polymorphism, Cowden syndrome, and *CHEK2* are suspected to be contributing factors in male breast cancer. Not to mention that Epidemiologic risk factors also plays an important role in male breast malignancies; these include hormonal imbalance disorders, such as obesity, testicular conditions (e.g., orchitis, orchiectomy, cryptorchidism, and mumps), and exposure to radiation. Suspected epidemiologic factors involve prostate cancer, prostate cancer treatment, gynecomastia, occupational exposures (e.g., electromagnetic fields, polycyclic aromatic hydrocarbons, and high temperatures), nutritional factors (e.g., red meat intake and fruit and vegetable use), and alcohol intake (4). In our patient there was a previous unexplained history of treatment of hormonal replacement therapy after he had undergone orchiectomy due to testicular cancer. There is no significant role of the chemotherapy among our studied patient to the formation of his breast cancer which is considered the second primary malignancy. For example, Cisplatin was not found to be associated with a remarkably elevated risk developing second malignancies compared with chemotherapy based on non-Cisplatin- regimens(8).

Those who have a history of testicular cancer, demonstrated significantly higher risk of developing second cancers particularly for testicular cancer, and this risk keeps being high even after 15 years of the initial diagnosis (9). In this case report, our patient is diagnosed with stage 4 breast ductal carcinoma 20 years later to being treated for testicular cancer.

Age-specific incidence patterns present that the male breast cancer biology is similar to late-onset breast cancer in women.



Breast CT scan

It is crucial to quote that incidence of breast cancer of similar nature which occur among males and females suggests that there are in common risk factors which influence both sexes, particularly Estrogen receptor-positive breast cancer (10).

Studies show that male breast cancers have high ratios in hormone-receptor expression. Almost 90% of male breast carcinomas have positive the estrogen receptor. Likewise, expression progesterone receptor represents 81% of male breast cancers. Consequently and notably, male breast cancers are more likely to express hormone receptors than female breast cancers, even after adjusting patient age, cancer stage and grade. (11)

The management plan was to refer the patient to the oncologist to follow up with a palliative modality as the patient has multiple metastatic spots in the liver and lung. radiotherapy (6 cycles AC) and stated Hormonal treatment (Tamoxifen) were commenced. There are restricted information regarding indications of male patients adjuvant radiotherapy,; however, in general, following the same guidelines which are adhered to in managing cases of female breast cancer are recommended when taking care of men with breast cancer (8). Adjuvant hormonal therapy clearly has a role in male breast cancer patients with hormone receptor-positive tumors. In case of advanced disease (metastatic setting) Tamoxifen has activity against male breast cancer (12).

## CONCLUSION

Male breast cancer is a rare condition that has a bad prognosis than typical female breast cancer. There are many factors that can predispose the patient to develop a second primary cancer in his life. There are a deficiency in the researches about the development of a second tumor after having a testicular tumor. No enough data about the epidemiology or prognosis of such a case.

## REFERENCE

1. Rusner C, Streller B, Stegmaier C, Trocchi P, Kuss O, McGlynn KA, Trabert B, Stang A. Risk of second primary cancers after testicular cancer in East and West Germany: a focus on contralateral testicular cancers. *Asian J Androl.* 2014 Mar-Apr;16(2):285-9. doi: 10.4103/1008-682X.122069. PMID: 24407180; PMCID: PMC3955342.
2. Karayiannakis AJ, Kakolyris S, Kouklakis G, Chelis L, Bolanaki H, Tsalikidis C, Simopoulos C. Synchronous breast and rectal cancers in a man. *Case Rep Oncol.* 2011 May;4(2):281-6. doi: 10.1159/000328995. Epub 2011 May 25. PMID: 21734883; PMCID: PMC3124462.
3. Grenader T, Goldberg A, Shavit L. Second cancers in patients with male breast cancer: a literature review. *J Cancer Surviv.* 2008 Jun;2(2):73-8. doi: 10.1007/s11764-008-0042-5. Epub 2008 Apr 1. PMID: 18648975.
4. Weiss, Joli R., Kirsten B. Moysich, and Helen Swede. "Epidemiology of male breast cancer." *Cancer Epidemiology and Prevention Biomarkers* 14.1 (2005): 20-26.
5. Liu N, Johnson KJ, Ma CX. Male Breast Cancer: An Updated Surveillance, Epidemiology, and End Results Data Analysis. *Clin Breast Cancer.* 2018 Oct;18(5):e997-e1002. doi: 10.1016/j.clbc.2018.06.013. Epub 2018 Jun 27. PMID: 30007834.
6. Konduri S, Singh M, Bobustuc G, Rovin R, Kassam A. Epidemiology of male breast cancer. *Breast.* 2020 Dec;54:8-14. doi: 10.1016/j.breast.2020.08.010. Epub 2020 Aug 22. PMID: 32866903; PMCID: PMC7476060.
7. Niewoehner CB, Schorer AE. Gynaecomastia and breast cancer in men. *BMJ.* 2008;336(7646):709-713. doi:10.1136/bmj.39511.493391.BE
8. Liang, F., Zhang, S., Xue, H., & Chen, Q. (2017). Risk of second primary cancers in cancer patients treated with cisplatin: A systematic review and meta-analysis of randomized studies. *BMC Cancer, 17*(1). <https://doi.org/10.1186/s12885-017-3902-4>
9. Gómez-Raposo, C., Tévar, F. Z., Moyano, M. S., Gómez, M. L., & Casado, E. (2010). Male breast cancer. *Cancer treatment reviews, 36*(6), 451-457.
10. Anderson WF, Jatoi I, Tse J, Rosenberg PS. Male breast cancer: a population-based comparison with female breast cancer. *J Clin Oncol.* 2010 Jan 10;28(2):232-9. doi: 10.1200/JCO.2009.23.8162. Epub 2009 Dec 7. PMID: 19996029; PMCID: PMC2815713.
11. Giordano, Sharon H. "A review of the diagnosis and management of male
12. breast cancer." *The oncologist* 10.7 (2005): 471-479  
Rudlowski C. Male Breast Cancer. *Breast Care (Basel).* 2008;3(3):183-189. doi:10.1159/000136825