

## Original Article

## Determination of Specific Anti - Toxocara Antibodies in Patients with Cardiac Disease

Eleonora Kaneva<sup>1</sup>, Rumen Harizanov<sup>1\*</sup>, Stefka Krumova<sup>2</sup>, Petya Genova-Kalu<sup>2</sup>, Iskra Rainova<sup>1</sup>, Nina Tsvetkova<sup>1</sup>, Iskren Kaftandjiev<sup>1</sup>, Mariya Pishmisheva<sup>3</sup>

Departments of <sup>1</sup>Parasitology and Tropical Medicine and <sup>2</sup>Virology, National Centre of Infectious and Parasitic Diseases, Sofia, Bulgaria;

<sup>3</sup>Department of Infectious Diseases, Hospital for Active Treatment "Pazardzhik" AD, Pazardzhik, Bulgaria

**Corresponding Author:** Rumen Harizanov, email: harizanov@ncipd.org

## ARTICLE INFO

## Article history

Received: April 07, 2021

Accepted: June 13, 2021

Published: July 31, 2021

Volume: 9 Issue: 3

Conflicts of interest: None

Funding: None.

Sponsoring information: none

## Key words:

Toxocariasis,  
Heart Disease,  
Differential Diagnosis,  
Western Blot,  
ELISA

## ABSTRACT

Aim of this study is to find the seroprevalence of specific anti - *Toxocara* IgG antibodies among patients with inflammatory heart disease and to evaluate the significance of this parasite as a possible etiological agent of such pathology. We performed a serological study of 41 patients with heart disease (myocarditis, pericarditis and endocarditis) for presence of specific anti-*Toxocara* IgG antibodies. We used ELISA for primary screening, and Western blot as a confirmatory method. Presence of specific anti-*Toxocara* IgG antibodies in ELISA was detected in three (7.3%) of the serum samples, and another two (4.9%) were with borderline values. These serum samples were further examined in Western blot and three of them (7.3%) displayed disease-specific bands. We do not in any way claim that in these cases *Toxocara* infection is the cause of inflammatory heart disease, but the data from the study shows that such a link is possible.

## INTRODUCTION

Toxocariasis is a parasitic zoonotic disease caused by the migration and presence of animal nematode larvae of the *Toxocaridae* family, most often by the species *Toxocara canis* (Werner, 1782) and *Toxocara cati* (Schrank, 1788), in human organs and tissues. The infection is acquired by ingestion of parasitic eggs from contaminated sources or by the consumption of insufficiently heat-treated meat and offal of infected animals. Reservoir hosts and sources of the disease are mainly dogs and cats, as well as other members of the *Canidae* and *Felidae* families, in the small intestine of which the parasites develop into sexually mature forms and emit eggs which under suitable environmental conditions will become embryonated and infectious. In infected humans, second stage larvae hatch from the swallowed eggs and through haematogenic route reach different organs and tissues, causing various pathological changes with a variety of clinical symptoms [1]. Once in tissues, the larvae encapsulate but remain metabolically active and secrete glycoprotein antigens that cause tissue damage, necrosis, inflammation and eosinophilia [2]. The pathological changes in toxocariasis are due to the

mechanical injury by the migrating larvae, the inflammatory response to their presence and their metabolic production [3]. The severity of the clinical manifestations depends on the affected organ, the number of migratory larvae, the age of the host, and severity of the induced immediate and delayed type of hypersensitivity reactions [4]. There are two major syndromes related to toxocariasis - Visceral Larva Migrants (VLM) with internal organ involvement [1] and Ocular Larva Migrants (OLM), which damages the eye [5, 6]. Visceral larva migrants affects mostly children and manifests with fever, enlargement of the liver and spleen, bronchospasm, eosinophilia and hypergammaglobulinemia [7]. More often affected are the liver [8], lungs [9] and CNS [10]. Migration of the *Toxocara* larvae in the cardiac tissues were described extremely rarely and usually were found in histological specimens of patients with other diseases. Extensive study of data in the literature by Kuenzli E. et al. in 2016 showed that of 134 patients with visceral toxocariasis, heart involvement was seen in only one of them [11]. The same authors summarized the published data on toxocariasis-related heart conditions, describing 24 cases, their clinical presentation, complications, treatment and outcome. According to them, heart damage in

toxocariasis most commonly occurs as myocarditis (58%), pericarditis (25%), Löeffler endocarditis (16.7%) or a combination of these [11]. Cardiac toxocariasis is considered to be a disease affecting all age groups, but is mostly found in children less than five years of age [12]. Its clinical presentation ranges from asymptomatic [13] or mild illness to a severe life-threatening condition [11] and is a result of direct invasion of larvae in the cardiac tissue resulting in granulomatous lesions and / or hypersensitivity reactions [14]. Studies in rats infected with *T. canis* have shown that activated eosinophils also cause damage to the heart, possibly due to their cytotoxic products [15]. The inability to detect parasitic larvae in the tissues and the lack of parasitic eggs significantly impedes the diagnosis of toxocariasis. The use of biopsy materials to diagnose the disease is the only method of accurate identification, but this procedure is invasive and carries a risk for the patient [16]. Therefore, the main diagnostic methods are currently immunological: ELISA based on the use of excretory / secretory antigens [17] and Western blot as a confirmation method [18]. As a peculiar and rare condition, cardiac toxocariasis can be diagnosed by finding a parasitic larva or eosinophilic granuloma in histological sections of cardiac tissue, a positive serological test combined with specific cardiac examinations - ECG, chest X-ray, echocardiography [11]. The lesions caused by *Toxocara* larvae can be identified by other imaging techniques such as computed tomography (CT) and magnetic resonance imaging (MRI) [19, 20].

Diagnosis of cardiac toxocariasis, however, is compounded by the difficult identification of the agent, the presence of non-specific signs and symptoms that may be found in heart diseases with different etiology, and the involvement of other organs and systems in the body. Literature data on the pathological changes caused by *Toxocara* larvae during their cardiac migration are controversial, and there are no data on controlled trials among such groups of patients.

Aim of our study is to find the seroprevalence of specific anti - *Toxocara* IgG antibodies among patients with inflammatory heart disease and to evaluate the significance of this parasite as a possible etiological agent of such pathology.

## METHOD

### Study Design

This research study was conducted retrospectively from data obtained for clinical purposes and epidemiological investigations carried out under Bulgarian legislation. All procedures performed in this study involving human participants were in accordance with the ethical standards of the Ethics Committee at the National Centre of Infectious and Parasitic Diseases, Sofia, Bulgaria (NCIPD), institutional review board (IRB) 00006384, and with the 1964 Helsinki declaration and its later amendments or comparable ethical standards.

### Serum Samples

Serum samples of patients with cardiovascular disease (n = 41) were provided to us by the Virology Department at the National Centre of Infectious and Parasitic Diseases

(NCIPD), where they were previously tested for cardiotropic viruses (n = 21) in the National Reference Laboratory (NRL) "Measles, mumps and rubella" [21] and for Q fever (n = 20) in the NRL "Rickettsiae and Cell Cultures" [22]. They were from patients with myocarditis (n = 8), pericarditis (n = 14), endocarditis (n = 16), cardiomyopathy (n = 1) and valvular prostheses (n = 2). The serum samples were obtained through the period 2013-2015 and were sent for diagnostic tests by different cardiac hospitals in the country. The serum samples were obtained by standard procedure and frozen at - 20 °C until testing.

### Sampling Procedures

Enzyme-linked immunosorbent assay (ELISA) to detect anti-*Toxocara* IgG antibodies, commercial kit (R-biopharm) performed according to the manufacturer's recommendations (positive - SR > 1.1; borderline between 0.9 - 1.1; negative - SR < 0.9).

Western blot (WB), commercial kit (LDBIO) performed according to the manufacturer's instructions. WB was used as confirmatory method when positive and borderline results were obtained in ELISA.

### Statistics and Data Analysis

Used was SPSS Version 20 statistical package (Descriptive statistics: frequencies, mean, Chi-square test). P ≤ 0.05 were considered statistically significant.

## RESULTS AND DISCUSSION

### Results

The studied sera samples were from 1 to 84 year old patients (mean 45 ± 21 years), 8 of them children, 33 adults; 21 males and 20 females (Table 1).

According to the initial diagnosis, 19% of them were with myocarditis, 33.3% with pericarditis, 38.1% with endocarditis and 7.1% with another diagnosis (cardiomyopathy and prosthetic valve replacement). Presence of specific anti-*Toxocara* IgG antibodies in ELISA was found in three of the serum samples (7.3%) and in another two (4.9%) the results were with borderline values. Negative for presence of specific anti-*Toxocara* IgG antibodies in ELISA were 36 (87.8%) of the serum samples. The mean value of the positivity index (SR) obtained in the ELISA for the three positive samples was 2.75 ± 1.06 (min = 2.08, max = 3.98, range 1.90), and for both borderline samples 0.98 ± 0.06 (min = 0.94; max = 1.02; range 0.08). With positive result in ELISA were two of 21 (9.5%) male patients, and one of 20 (5%) female patients. In two female patients (10%) the ELISA test was with borderline values. There was no statistically significant relationship between the sex of the patients and their toxocariasis seropositivity in ELISA (p = 0.298).

Out of eight tested children and adolescents only one (12.5%) was with presence of anti-*Toxocara* antibodies, and from 33 patients over the age of 18 two (6.1%) were positive

**Table 1.** The results of ELISA test distributed by gender, age and clinical diagnosis among patients with heart disease.

	ELISA (positive)	ELISA (borderline)	ELISA (negative)	p-value
Gender				
- male	2 (9.5%)	0 (0%)	19 (91%)	0.298
- female	1 (5%)	2 (10%)	17 (85%)	
Age group				
- 0-18	1 (12.5%)	0 (0%)	7 (87.5%)	0.654
- > 18	2 (6.1%)	2 (6.1%)	29 (87.9%)	
Clinical diagnosis				
- miocarditis	1 (12.5%)	0 (0%)	7 (87.5%)	0.969
- pericarditis	1 (12.5%)	1 (7.1%)	12 (85.7%)	
- endocarditis	1 (12.5%)	1 (7.1%)	14 (87.5%)	

in ELISA and two (6.1%) were with borderline values (Table 2). No statistically significant differences ( $p = 0.65$ ) were found between the age of the patients and the results obtained in ELISA.

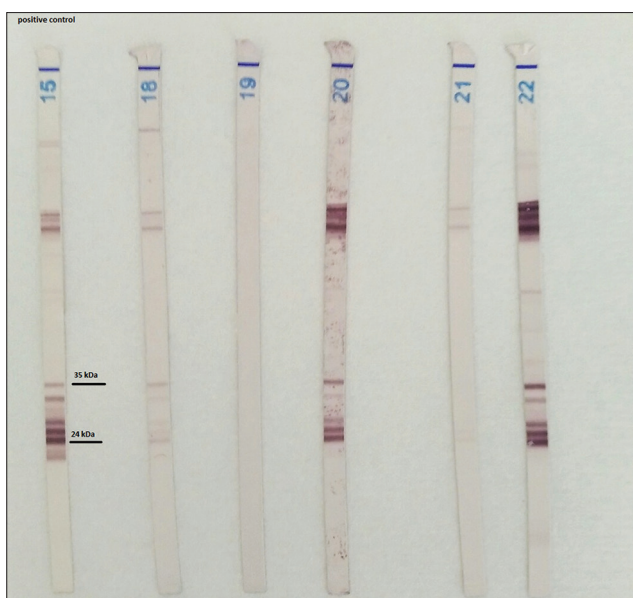
According to the initial diagnosis, presence of specific anti-*Toxocara* antibodies was found in one patient with myocarditis (12.5% of those diagnosed with this diagnosis), one with pericarditis (7.1%) and one with endocarditis (6.2%). The two borderline results are of a patient with pericarditis and a patient with endocarditis. There was no statistically significant relationship between the seroprevalence for toxocariasis in ELISA and the initial diagnosis ( $p = 0.97$ ). The serum samples of patients with positive and borderline results in ELISA were also tested in WB for confirmation. We found presence of specific bands characteristic of toxocariasis in three of them (7.3%) – a 57 years old woman with pericarditis, 84 years old man with pericarditis and 53 years old woman with endocarditis (Figure 1, Table 2).

## Discussion

Inflammatory diseases of the heart are associated with various infectious agents [23], viruses [24], rickettsia [25] and bacteria [26]. There is evidence that some protozoa and helminths can also cause heart damage resulting either from generalized disease (African trypanosomiasis) or from direct effect of the parasite on various cardiac structures (myocardium, pericardium, endocardium or heart vessels). Latent parasitic infections can also be reactivated and manifested as systemic heart disease, which most often is seen in immunosuppressed individuals [27]. It has been found that the larvae of *Toxocara* spp. can affect the heart during their migration through the human body [13, 14, 28]. There have been cases of myocarditis, pericarditis or Löeffler's endocarditis, with myocarditis being a more common clinical manifestation. The disease may be asymptomatic [13] or severe, with acute heart failure or cardiac tamponade [29]. Clinical manifestations are expressed with chest pain, dyspnea and hypotension, which also are often seen in heart failure, and are completely unspecific [11]. *Toxocara* larvae are usually found randomly at autopsy or histological samples of patients who died or who had undergone surgery for other diseases [30]. Main

**Table 2.** Seroprevalence of toxocariasis among patients with heart disease by ELISA and Western blot.

Nº	Gender	Age	Diagnosis	ELISA (SR)	WB
1.	female	57	pericarditis	1.02	(+)
2.	male	84	pericarditis	2.08	(+)
3.	male	10	myocarditis	2.2	(-)
4.	female	64	endocarditis	0.94	(-)
5.	female	53	endocarditis	3.98	(+)

**Figure 1.** Results in WB of serum samples with positive and borderline results in ELISA (no 15 – positive control, no 18, 20, 22 display disease-specific bands)

indicator that may point to a specific parasitological diagnosis is the presence of eosinophilia, but there is still no single opinion on its occurrence in such patients, and eosinophilic cell levels do not always correlate with the severity of heart involvement [11]. The diagnosis can be made by finding larvae or granulomas formed by them in biopsy specimens obtained from affected heart tissues [13]. Due to the fact that such test samples usually are not available, basic diagnostic

methods are the serologic tests for detection of specific IgG antibodies against *Toxocara* antigens.

Our study has data for 7.3% seroprevalence among subjects with inflammatory heart diseases in ELISA, and a similar result (7.3%) in WB. Two of the cases confirmed by WB were patients with pericarditis and one with endocarditis. Toxocariasis is a disease affecting mostly children [1, 7] and there are data that toxocariasis related myocarditis more often is observed among them [12], but in the examined by us group with positive results in ELISA were mostly adult patients. Although there is a statistically significant correlation between the diagnosis and seropositivity, only those over the age of 18 were positive in the confirmatory WB test. In the literature, *T.canis* is described as a causative agent of myocarditis [13, 14, 28, 30], but our study did not find presence of anti-*Toxocara* IgG antibodies in any of the patients with myocarditis.

In a previous study of 50 clinically healthy subjects (32 men and 18 women), we found 6% (n = 3) seroprevalence for toxocariasis in ELISA and 4% (n = 2) in WB [31]. Comparison among the group of the patients with inflammatory heart disease and the group of clinically healthy blood donors showed relatively higher prevalence of specific anti-*Toxocara* antibodies in the first group (7.3% versus 6% in ELISA and 7.3% vs. 4% in WB), but the positive serology is not sufficient to provide a definitive diagnosis and the statistical comparison showed no significant difference (2X2 contingency table, Fisher's exact test, p=0.654). One reason is that specific antibodies are retained in the body for years [32] and determination of their levels is not indicative for the stage of disease and the effect of treatment. Consequently, a positive result from toxocariasis serology detecting specific IgG may be fortuitously associated with any pathological condition. This situation is not specific to toxocariasis and can be observed with other infections displaying a similar global seroprevalence, such as toxoplasmosis or hepatitis A. For this kind of protozoal or viral (and also bacterial) infections, discrimination between the presence of residual antibodies without any diagnostic importance and a positive serology result due to an active, current disease has been achieved by the detection of specific IgM antibodies, and more recently, by molecular methods. Unfortunately, none of them applies to toxocariasis, so a diagnosis of active toxocaral disease relies upon circumstantial evidences that are primarily the presence of blood eosinophilia and, at a lesser degree, an increase of total serum IgE.

Detailed information on the interpretation of serological results in cardiac toxocariasis is still lacking. Careful evaluation is needed, taking into account clinical signs, eosinophil levels and possible cross-reactions with other parasites. Diagnosis of the disease should exclude noninfectious causes, various infectious agents or other parasites [23, 27]. Myocarditis caused by *Toxocara* spp. cannot be distinguished from that caused by other etiological agents and toxocariasis may be a co-infection that is not responsible for the cardiac manifestations. According to Kuenzli, et al. (2016), for diagnosing the disease, the patient needs to meet at least 2 out of 3 criteria - a positive serologic test, an increase in the

specific antibody titers during or after treatment, or eosinophilia (> 500/ $\mu$ l). Our serologic tests found low levels of specific anti-*Toxocara* IgG antibodies in ELISA in patients with inflammatory heart disease, which required serum samples to be further investigated by a confirmatory method. Western blot is a recommended confirmatory serologic method for diagnosis of toxocariasis and should be administered to patients with positive or borderline results in ELISA [18, 33].

## CONCLUSION

Our study is a pilot on a relatively small number of sera from patients with inflammatory heart disease in whom no viral etiology of the condition was detected and retrospectively examined for the presence of anti - *Toxocara* specific antibodies, with a view to establishing a possible association between visceral toxocariasis and involvement of the heart. We do not in any way claim that in these cases toxocara infection is the cause of inflammatory heart disease, because we do not have convincing evidence that the patients studied have a current infection, but the data from the study shows that such a link is possible. The exact etiological diagnosis of inflammatory heart disease in many cases may be crucial for the final outcome of the disease. For this reason, the differential diagnosis should include all possible pathogens - potential causative agents, including rarely diagnosed ones such as *Toxocara* spp.

## Abbreviations List

Computed tomography = CT, Electrocardiogram = EKG, Enzyme-linked immunosorbent assay = ELISA, Institutional Review Board = IRB, Magnetic resonance imaging=MRI, Microliter =  $\mu$ l, Ocular Larva Migrans=OLM, Visceral Larva Migrans=VLM, Western blot = WB

## Author Contributions

All authors contributed toward literature search, drafting and critically revision of the paper and agree to be accountable for all aspects of the work.

## Acknowledgements

Not applicable.

## Ethical issues

All procedures performed in this study involving human participants were in accordance with the ethical standards of the Ethics Committee at the National Centre of Infectious and Parasitic Diseases, Sofia, Bulgaria (NCIPD), institutional review board (IRB) 00006384, and with the 1964 Helsinki declaration and its later amendments or comparable ethical standards

## Informed Consent

Not applicable in connection with the retrospective nature of the study.

## REFERENCES

1. Beaver P, Snyder C, Carrera G, Dent J, Lafferty J. Chronic eosinophilia due to visceral larva migrans: report of three cases. *Pediatrics* 1952;9:7-19.
2. Xinou E, Lefkopoulos A, Gelagoti M, et al. CT and MR imaging findings in cerebral toxocaral disease. *Amer J Neuroradiol* 2003;24(4): 714-718.
3. Page A, Hamilton A, Maizels R. *Toxocara canis*: monoclonal antibodies to carbohydrate epitopes of secreted (TES) antigens localize to different secretion-related structures in infective larvae. *Exp Parasitol* 1992;75(1): 56-71.
4. Despommier D. Toxocariasis: Clinical aspects, epidemiology, medical ecology and molecular aspects. *Clin Microbiol Rev* 2003;16(2):265-272.
5. Wilder HC. Nematode endophthalmitis. *Trans Am Acad Ophthalmol Otolaryngol* 1950;55: 99-109.
6. Taylor M, Keane C, O'Connor P, Mulvihill E, Holland C. The expanded spectrum of toxocaral disease. *Lancet* 1988;1(8587):692-5.
7. Glickman L, Schantz P, Cypess R. Epidemiological characteristics and clinical findings in patients with serologically proven Toxocariasis. *Trans R Soc Trop Med Hyg* 1979;73(3): 254-8.
8. Hartleb M, Januszewski K. Severe hepatic involvement in visceral larva migrans. *Eur J Gastroenterol Hepatol* 2001;13(10): 1245-1249.
9. Kuziemski K, Jassem E, Mierzejewska E. Lung manifestation of visceral larva migration syndrome due to *Toxocara canis* infection. *Pneumonol Alergol Pol* 1999;67(11-12): 554-557.
10. Magnaval JF, Galindo L, Glickman T, Clanet M. Human *Toxocara* infection of the central nervous system and neurological disorders: a case-control study. *Parasitology* 1997;115(Pt 5): 537-543.
11. Kuenzli E, Neumayr A, Chaney M, Blum J. Toxocariasis-associated cardiac diseases – A systematic review of the literature. *Acta Tropica* 2016;154: 107-120. doi: 10.1016/j.actatropica.2015.11.003.
12. Lee R, Moore L, Bottazzi M, Hotez P. Toxocariasis in North America: a systematic review. *PLoS Negl Trop Dis* 2014;8(8):e3116. doi: 10.1371/journal.pntd.0003116.
13. Dao A, Virmani R. Visceral larva migrans involving the myocardium: report of two cases and review of the literature. *Pediatr Pathol* 1986;6(4): 449-456.
14. Abe K, Shimokawa H, Kubota T, Nawa Y, Takeshita A. Myocarditis associated with visceral larva migrans due to *Toxocara canis*. *Intern Med* 2002;41(9): 706-708.
15. Schaffer S, Dimayuga E, Kayes S. Development and characterization of a model of eosinophil-mediated cardiomyopathy in rats infected with *Toxocara canis*. *Am J Physiol* 1992;262(5 Pt 2):H1428-34.
16. Woodruff A. Toxocariasis. *Br Med J* 1970;3(5724):663-9.
17. De Savigny D. In vitro maintenance of *Toxocara canis* larvae and a simple method for the production of *Toxocara* ES antigen for use in serodiagnostic tests for visceral larva migrans. *J Parasitol* 1975;61(4): 781-782.
18. Magnaval JF, Fabre R, Maurières P, Charlet JP, de Larrard B. Application of the western blotting procedure for the immunodiagnosis of human toxocariasis. *Parasitol Res* 1991;77(8), 697-702.
19. Baldisserotto M, Conchin C, Da Soares M, Araujo M, Kramer B. Ultrasound findings in children with toxocariasis: report on 18 cases. *Pediatr Radiol* 1999;29(5): 316-319.
20. Dupas B, Barrier J, Barre P. Detection of *Toxocara* by computed tomography. *Br J Radiol* 1986;59(701): 518-519.
21. Ivanova S, Angelova S, Stoyanova A, et al. Serological and molecular biological studies of Parvovirus B19, Coxsackie B Viruses, and Adenoviruses as a potential cardiotropic viruses in Bulgaria. *Folia Medica* 2016;58 (4): 250-255. doi:10.1515/folmed-2016-0036
22. Genova-Kalou P, Ivanova S, Pavlova A, Trendafilova E, Pencheva D. Seroepidemiological and molecular biology study of *Coxiella Burnetii* in laboratory samples of patients with cardiac complications. Sixteenth national congress of Clinical Microbiology and Infections of Bulgarian Association of Microbiologists. Sofia, May 10-12, 2018. Park-hotel „Moskva”. Abstract book, pp.39-40.
23. Drory Y, Turetz Y, Hiss Y, et al. Sudden unexpected death in persons less than 40 years of age. *Am J Cardiol* 1991;68 (13): 1388-92.
24. Bowles N, Vallejo J. Viral causes of cardiac inflammation. *Curr Opin Cardiol* 2003;18 (3): 182-8.
25. Shah S, McGowan J. Rickettsial, ehrlichial and Bartonella infections of the myocardium and pericardium. *Front Biosci* 2003;8: e197-201.
26. Wasi F, Shuter J. Primary bacterial infection of the myocardium. *Front Biosci* 2003;8: s228-231.
27. Hidron A, Vogenthaler N, Santos-Presiado J, Rodriguez-Morales A, Franco-Paredes C, Rassi A Jr. Cardiac involvement with parasitic infections. *Clin Microbiol Rev* 2010;23(2):324-49. doi: 10.1128/CMR.00054-09.
28. Kim J, Chung W, Chang K, et al. Eosinophilic myocarditis associated with visceral larva migrans caused by *Toxocara canis* infection. *J Cardiovasc. Ultrasound* 2012;20(3):150-3. doi: 10.4250/jcu.2012.20.3.150.
29. Becroft D. Infection by the dog roundworm *Toxocara canis* and fatal myocarditis. *N Z Med J* 1964;63: 729-732.
30. Vargo T, Singer D, Gillette P, Fernbach D. Myocarditis due to visceral larva migrans. *J Pediatr* 1977;90(2): 322-323.
31. Kaneva E, Rainova I, Harizanov R, Nikolov G, Kaftandjiev I, Mineva I. Study of *Toxocara* seroprevalence among patients with allergy and healthy individuals in Bulgaria. *Parasite Immunol* 2015;37(10): 505-509. doi: 10.1111/pim.12217.
32. Cypess R, Karol M, Zidian J, Glickman L, Gitlin D. Larva-specific antibodies in patients with visceral larva migrans. *J Infect Dis* 1977;135(4):633-640.
33. Lynch N, Wilkes L, Hodgen A, Turner K. Specificity of *Toxocara* ELISA in tropical populations. *Parasite Immunol* 1988;10: 323-337.