

Case Report**Left Eye Conjunctivitis: An Isolated Presentation of COVID-19 Infection: A Rare Case Report**D. C. Kumawat¹, Navgeet Mathur^{2*}, Rachit Saxena³, Taniya Upadhyaya³, Medha Mathur⁴¹Head of the department, Professor, Department of General Medicine, Geetanjali Medical College and Hospital, Udaipur, Rajasthan, India²Assistant Professor, Department of General Medicine, Geetanjali Medical College and Hospital, Udaipur, Rajasthan, India³Resident Doctor, Department of General Medicine, Geetanjali Medical College and Hospital, Udaipur, Rajasthan, India⁴Assistant Professor, Department of Community Medicine, Geetanjali Medical College and Hospital, Udaipur, Rajasthan, India**Corresponding Author:** Dr. Navgeet Mathur, E-mail- mathurdrnavgeet@gmail.com**ARTICLE INFO***Article history*

Received: January 04, 2020

Accepted: March 12, 2021

Published: April 30, 2021

Volume: 9 Issue: 2

Conflicts of interest: None

Funding: None.

Key words:Conjunctivitis,
COVID 19,
Pandemic,
Pneumonitis,
RT-PCR**ABSTRACT**

The world is having COVID 19 pandemic currently. Early diagnosis is a challenge as the COVID 19 illness has variety of presentations. In this regard knowledge about spectrum of clinical presentation may be very helpful. This case report was about presentation of COVID 19 illness as isolated left eye conjunctivitis in a 58 years old male patient. By early diagnosis and appropriate treatment, the patient was recovered completely as well as his positive contacts were also isolated immediately. The study also highlighted the need of awareness among clinicians about isolated left eye conjunctivitis presentation of COVID 19.

INTRODUCTION

COVID-19 outbreak was first reported in Wuhan, China in December 2019. Afterward, it spread quickly around the world and became a global pandemic. Presentation of COVID-19 illness may be anything between asymptomatic to severe illness and mortality. Common symptoms are fever, fatigue, muscle or body aches, cough, sore throat, congestion of nose, shortness of breath, headache, recent loss of taste or smell, nausea, vomiting, diarrhea^[1-4]. It is known to involve respiratory system most commonly. It may involve multiple systems and there is a diagnostic challenge due to variety of presentations. Early diagnosis and treatment can minimize morbidity and mortality. Early diagnosis is also helpful to minimize spread of infection. This case report is about COVID 19 infection presenting solely as isolated left eye conjunctivitis.

CASE REPORT

A 58 years old male patient presented on January, 2021 with left eye redness and itching for last 6 days, associated with mild bodyache for one day. He consulted an ophthalmologist,

given anti allergic eye drop and antibiotic (eye drop levofloxacin 0.5 % solution) for local installation without relief. Redness of left eye was of insidious onset in the morning 6 days back, He got little relief in itching but redness of eye was not relieved even after 6 days of medication, additionally he developed bodyache for last one day. There was no history of fever, chills, rigor, sore throat, running nose, sneezing, shortness of breath, burning micturition, diarrhea, local trauma or ocular pain.

There was no significant history of past illness and he was not on any kind of medication before the illness. He had no history of diabetes, hypertension, tuberculosis and allergic disorder. No family members were having similar illness. The patient was nonsmoker, non alcoholic.

His blood pressure was 124/82 mm of Hg , pulse- 84/minute, regular and respiratory rate- 16/minute. SpO2 was 97% on room air. On general physical examination no abnormality was found except redness of left eye (Figure 1). Systemic examination was normal.

As the patient had left eye conjunctivitis and bodyache, infective etiology was thought. In view of current

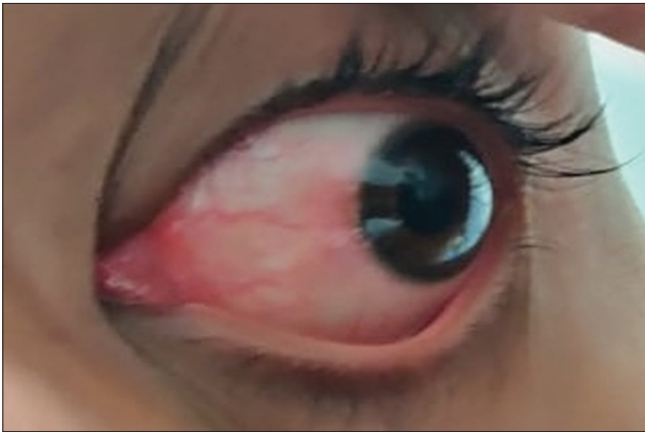


Figure 1. Showing left eye conjunctivitis

pandemic, literature was reviewed and left eye conjunctivitis was found to be one of the COVID 19 presentation. His Hemoglobin was 16.0 mg/dl, total leukocyte count was 10,700/cumm, neutrophils were 76%, lymphocytes were 14.3 %, monocytes were 7.2%, eosinophils were 2.1%, platelet count was 329000/cumm, random blood sugar was 118 mg/dl, renal and liver function test were within normal limits.

ECG was normal. Malaria antigen test was negative and peripheral blood film was normal. Dengue NS1 antigen, Dengue IgM, IgG antibodies, Typhoid IgM, IgG antibodies were negative. Reverse transcriptase- Polymerase Chain Reaction (RT-PCR) for COVID 19 of throat and nasopharyngeal swab was positive. His serum d- Dimer, IL-6, CRP level, Ferritin, LDH were normal. HRCT thorax was suggestive of bilateral pneumonitis with CT score of 8/25 indicating lung involvement due to COVID 19 infection. Diagnosis of COVID 19 illness with bilateral pneumonitis with left eye conjunctivitis was made.

His wife and 24 years old daughter were living with him and found COVID 19 RT PCR test positive although they were completely asymptomatic and SpO2 was 98%. The patient wished to stay at home isolated as he was having mild symptoms. He was treated according to the standard institutional treatment protocol of COVID 19 disease with home isolation. He was treated with favipiravir, tablet doxycycline, tablet ivermectin, Tablet vitamin c + zinc acetate, tablet levocetirizine + montelukast and tablet paracetamol 650 mg as per need. He was telephonically followed up every day. The patient improved after treatment, left eye conjunctivitis was recovered fully within 3 days of treatment and he took occasionally paracetamol for bodyache. No further signs and symptoms appeared and SpO2 remained within normal limits throughout the course.

DISCUSSION

The current case report highlighted the isolated left eye conjunctivitis presentation of COVID 19 illness and related diagnostic and management approach. Knowledge of the clinical spectrum of COVID 19 may help greatly

in early diagnosis of the disease and minimize morbidity and mortality. Early diagnosis and timely isolation also prevent the spread of infection. There are only few case reports about isolated conjunctivitis as a presenting feature of COVID 19 illness. The case report by Guo D et al^[1] also reported COVID 19 induced left eye conjunctivitis and reoccurrence of conjunctivitis in both eyes after 5 days of resolution. Ozturker ZK^[2] also reported a case of isolated right sided conjunctivitis as a presentation of COVID 19 illness. The case report by Markezan MC et al^[3] reported severe conjunctivitis in right eye followed by left eye after 4 days of fever and myalgia in COVID 19 patient. Chen L et al^[4] reported bilateral conjunctivitis in a COVID 19 patient and also demonstrated the presence of viral RNA in conjunctival specimen by RT PCR assay.

In the current case report patient consulted an ophthalmologist before but the patient was not investigated for COVID 19 probably due to lack of awareness about the presentation of isolated conjunctivitis. Awareness among clinicians is needed about the isolated left eye conjunctivitis presentation of COVID 19 infection. Knowledge of the entity and early diagnosis may help greatly in treatment and prevention of spread of infection to others.

CONCLUSION

Isolated left eye conjunctivitis can be a presenting feature of COVID 19 infection. Early diagnosis and treatment may relieve signs and symptoms completely as in the present case. Awareness about this atypical clinical presentation is needed among clinicians to minimize morbidity, mortality and spread of infection.

Consent for Publication

Informed written consent was obtained from patient to publish this case.

Ethical Approval

Ethical approval is not required at our institution to publish an anonymous case report.

Ethical Issues

Written consent was taken from the patient. Ethical committee approval not needed in our institute for case reports.

REFERENCES

1. Guo D, Xia J, Wang Y, Zhang X, Shen Y, Tong JP. Relapsing viral keratoconjunctivitis in COVID-19: a case report. *Virology* . 2020;17:97. <https://doi.org/10.1186/s12985-020-01370-6>
2. Ozturker ZK. Conjunctivitis as sole symptom of COVID-19: A case report and review of literature. *Eur J Ophthalmol*. 2020;24:1120672120946287. <https://doi.org/10.1177/1120672120946287>

3. Marquezan MC, Marquezam JP, Nascimento H, Chalita MR, Freitas DD, Belfort R. Conjunctivitis Related to not Severe COVID-19: A Case Report, *Ocular Immunology and Inflammation*. 2020. <https://doi.org/10.1080/09273948.2020.1837186>
4. Chen L, Liu M, Zhang Z, Qiao K, Huang T, Chen M, et al. Ocular manifestations of a hospitalised patient with confirmed 2019 novel coronavirus disease. *British Journal of Ophthalmology* 2020; **104**:748-751. <http://dx.doi.org/10.1136/bjophthalmol-2020-316304>