

Case Report**Taking Charge of Recurrence of a Glomus Tumor: About a Case and the Review of the Literature**

Badaoui Reda^{1*}, Elmaqrout Amine¹, Zaizi Abedrahim², Mekaoui Jalal², Boukhriss Jalal³, Chafry Bouchaib³, Benchaba Driss³, Boussouga Mostapha³

¹Resident in Orthopedic Surgery and Traumatology, Department of Orthopedic Surgery and Traumatology 2, Military Hospital Mohammed V (HMIMV), Faculty of Medicine and Pharmacy, University Mohammed V, BP 10100 Rabat, Morocco

²Specialist in Orthopedic Surgery and Traumatology, Department of Orthopedic Surgery and Traumatology 2, Military Hospital Mohammed V (HMIMV), Faculty of Medicine and Pharmacy, University Mohammed V, BP 10100 Rabat

³Professor in Orthopedic Surgery and Traumatology, Department of Orthopedic Surgery and Traumatology 2, Military Hospital Mohammed V (HMIMV), Faculty of Medicine and Pharmacy, University Mohammed V BP 10100 Rabat, Morocco

Corresponding Author: Badaoui Reda, E-mail: joudbadaoui17@gmail.com

ARTICLE INFO*Article history*

Received: July 04, 2020

Accepted: September 26, 2020

Published: October 30, 2020

Volume: 8 Issue: 4

Conflicts of interest: None

Funding: None.

Key words:

Lomus Tumors,

Benign,

Recurrence

ABSTRACT

Glomus tumors of the hand are benign vascular tumors, which develop at the expense of the neuro-myo-arterial glomus. They represent about 1% -5% of all hand tumors. Their diagnosis is frequently delayed by the absence of specific signs, its confirmation is based on anatomopathological examination. Their treatment is based on complete surgical excision and restitution of the nail apparatus, the only guarantees of a good evolution without recurrence. We report the case of a recurrence of a glomus tumor of the ring finger in a woman where the pains reappeared 6 months after the first intervention.

INTRODUCTION

The glomus tumor is a very rare benign neuromyo-arterial proliferation, initially described by Masson [1], their favorite site is the hand, particularly the subungual region and the lateral surface of the fingers. The clinical symptomatology is little known, which explains a frequent diagnostic delay. The interest of the radiological assessment is discussed, diagnostic certainty is provided by histology. In all cases, the treatment is surgical and is based on complete excision. Recent work shows that recurrences are not uncommon [2,3].

The goal of this work is to define, recurrences, the contributing factors and how to avoid them.

PATIENT AND OBSERVATION

A 45 year old woman, manual worker, without ATCD, who has had pain for 3 years, from the distal end of the ring finger, spontaneous, exacerbated by the slightest pressure and accentuated by the cold. The patient benefited from a surgical intervention, in another establishment, after an ultrasound exploration, where an exegesis of a tumor mass was carried

out, the diagnosis of a glomus tumor was retained after histological examination. In front of the reappearance of the symptomatology 6 months after the surgical operation, the patient consulted our establishment a year later. The clinical examination revealed a scar from the anterior latero-nail intervention, with no palpable mass or nodular or reduction in the articular amplitudes of the finger (Figure 1). All three tests (de love, cold water immersion and Hildreth's ischemia) were positive. The patient benefited from an ultrasound exploration which objectified a small hypoechogenic, oval, well limited nodule, vascularized with doppler, on the external face of the 3rd phalanx of the ring finger (Figure 2). An MRI was performed which objectified an infra-centimeter mass, in T1 hyposignal and T2 hypersignal, evoking a glomus tumor (Figure 3). An exegesis biopsy was performed, using the old incision, with a microscopic technique (Figure 4). Histological examination of the part (Figure 5) allowed the diagnosis of certainty of a recurrence of a glomus tumor.

The immediate aftercare was simple. After an 18-month follow-up, the patient reported a safe transformation in their daily lives, with no recurrence.

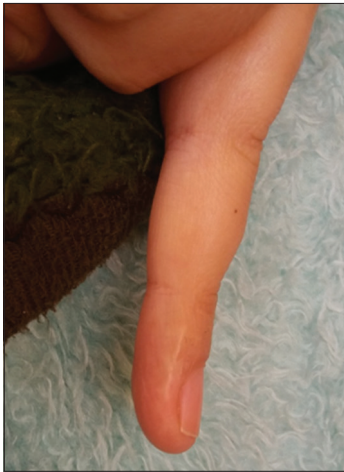

Figure 1. Recurrence of a glomus tumor

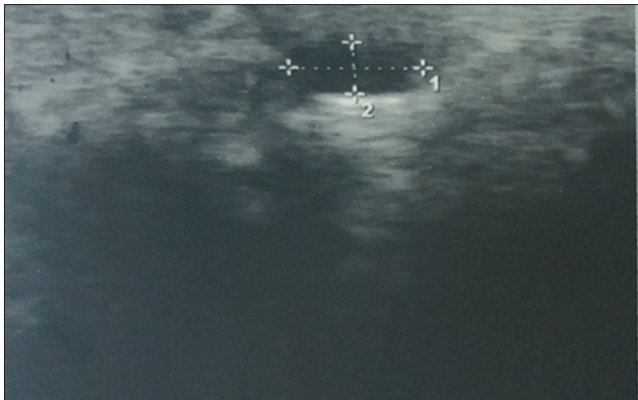


Figure 2 . Ultrasound of the finger showing a hypoechoic oval, well limited nodule

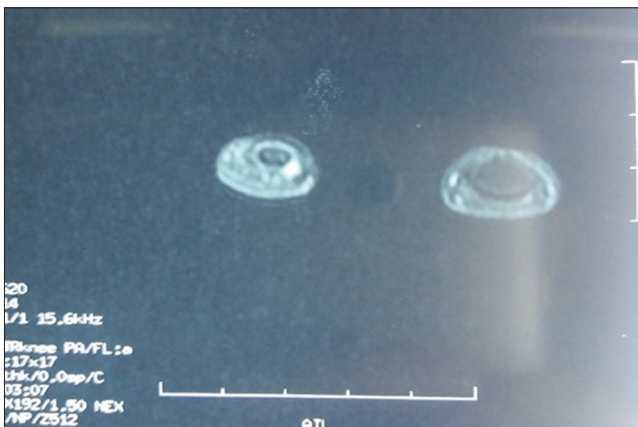


Figure 3. MRI of the hand showing a nodular hypersignal image

DISCUSSION

Masson's glomus tumor [1] is a benign tumor formed at the expense of neuromyo-arterial tissue, located at the level of capillary-venous anastomoses of regulation, particularly numerous, at the level of the digital extremities. These tumors are rare, but not exceptional [4], their frequency varies from 1.6 to 5% of all tumors of the soft parts of the hand [5,6]. It mainly affects young adults of the female sex, and sits with predilection at the ends of the fingers and particularly under the nail.

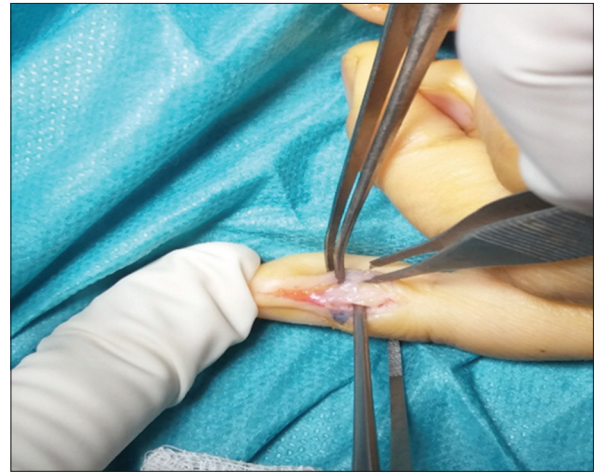

Figure 4. Intraoperative view of the tumor by inguile latero approach

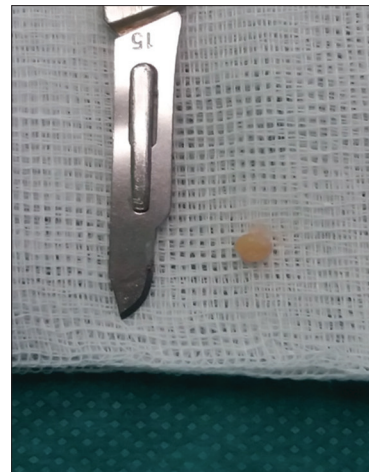

Figure 5. Appearance of the tumor after excision

The diagnosis is evoked before a small painful nodule of the extremities associated with a characteristic triad: cold hypersensitivity of the affected area, paroxysmal pain and exquisite pain on touch. The diagnosis of certainty is based on a bundle of arguments because only histology is formal. The clinic, when it is typical, can alone be sufficient for the diagnosis. However, the surgeon requests evidence of the existence of a tumor of the finger, and wishes to know precisely its location which determines the surgical approach, medial trans-nail or lateral.

Complete surgical excision of the glomus tumor remains the treatment of choice, it makes it possible to obtain indolence and avoid recurrence by a total excision of the tumor and its environment [7,8], in cases where the limits of the tumor are unclear due to hemorrhage, complete removal of the tumor is often not possible and the possibility of tumor recurrence is probable [9].

Recent work shows that recurrences are not rare, according to the authors, 4 to 24% of patients require a new intervention [2,3], however recent literature indicates that the rate of recurrence can reach 50% [10]. Early recurrence (less than a year) is considered to be the result of incomplete excision [3] or the presence of a second tumor that was not diagnosed and excised during the first intervention [11]. In our patient, there

is no evidence of incomplete excision, nor of the presence of a second undiagnosed tumor, since the patient did not benefit from a preoperative MRI. Late recurrence (more than a year) is attributed to the development of a new lesion in or near the same excision site [8]. It is not always possible to differentiate between a real recurrence and a new lesion [12]. Thus, most authors believe that recurrences are due to incomplete excision [3, 13,14], and that the probability of recurrence is higher in the case of: subungual glomus tumors [15, 16] or a tumor with color close to that of the skin [17,18]. For Straham [14], recurrence is the rule when the tumor is found to be unencapsulated during the first intervention. Therefore, in front of symptoms which persist more than 3 months after excision, it is strongly recommended to re-explore [16]. Heim and Hanggi [19] report in their series that the number of patients with early recurrence was almost equal to that of patients with late recurrence, with a slight predominance of early recurrences (54%). In Madhar.M's series [20], no tumor recurrence has been observed. Several measures have been maintained in order to ensure complete excision and reduce the rate of recurrence: some authors [14,21, 22,23] recommend excision wider than the apparent limits of the tumor, microscopic surveillance [24] or intraoperative ultrasound [25] can also be useful to ensure adequate resection, finally a procedure of exsanguination of the finger by a double tourniquet (one at mid-height and the other at the root of the finger) has also been proposed to better visualize the tumor intraoperatively [18]. Percutaneous sclerotherapy can be used to treat recurrent glomus tumors [26].

CONCLUSION

Recurrences of glomus tumors are not uncommon, for this, several measures must be taken: a preoperative MRI, an excision wider than the apparent limits of the tumor, by a microscopic technique or under ultrasound control.

ACKNOWLEDGEMENT

We want to acknowledge Madame SABRA BEZZANIN for her helpful revision of the English language.

REFERENCE

1. Masson P. Le glomus neuro-myo-arteriel des regions tactiles etses tumeurs. Lyon Chi.1924;21:257-80.
2. Carlstedt T, Lugnenard H: Glomus tumors of the hand. A clinical and morphological study. Acta Orthop Scand, 1983, 54: 296-302.
3. Carroll E R, Berman A T: Glomus tumors of the hand; J Bone Joint Surg(Am); 1972; 54A; N°4: 691- 703.
4. Raimbeau G, Mallet J, Fondimare A, Tirouflet D. Tumeurs glomiques des doigts (à propos de 6 cas personnels). Ann OrthopOuest 1984;16:85.
5. Glicenstein J, Ohana J, Leclercq C. Tumeurs de la main. Berlin:Springer Verlag; 1988, p. 143-9.
6. Vandevender DK, Daley RA. Benign and malignant vascular tumors of the upper extremity. Hand Clin 1995;11:161—81.
7. Vasisht B, Watson HK, Joseph E et al. Digital glomus tu-mors: a 29-year experience with a lateral subperiosteal ap-proach. PlastReconstr Surg. 2004;114(6):1486-9.
8. Van Geertruyden J, Lorea P, Goldschmidt D et al. Glomustumours of the hand: a retrospective study of 51 cases. J Hand Surg Br.1996;21:257-60.
9. Takei TR, Nalebuff EA. Extradigitalglomustumour. J Hand Surg Br.1995;20:409-12.
10. Brenner P, Krause-Bergmann A, Wittig K. Solitary glomus tumors of the hand.A clinico-pathologic evaluation study. Langenbecks Arch Chir 1995;380:321—6.
11. Gandon F, Legaillard P, Brueton R, Le Viet D, Foucher G. Forty-eight glomus tumours of the hand: retrospective study and four-year follow-up. Ann Chir Main Memb Super. 1992;11:401—405.
12. David T. Netscher, MD, Jaime Aburto, MD, Matthew Koepplinger, DO Subungual Glomus Tumor JHS _Vol 37A, April 2012.
13. Priollet P., Bruneval P., Laurian C., Dezellus P., Vaysairat M., Housset E : Tumeurs glomiques sous unguéales, à propos d'un cas. Rev. Med. Interne. 1985; 6; 121-125.
14. Strahan J., Bailie H.V. Glomus tumor, a review of 15 clinical cases. Br.J. Surg, 1972, 59:92, 95.
15. Lin YC, Hsiao PF, Wu YH, Sun FJ, Scher RK.Recurrent digital glomus tumor: Analysis of 75 cases. Dermatol Surg 2010;36:1396—1400.
16. Netscher DT, Aburto J, Koepplinger M.Subungual glomus tumor. J Hand Surg Am. 2012;37:821—823.
17. Baran R, Haneke E. Tumours of the nail apparatus and adjacent tissues. In: Baran R, Dawber RPR, editors. Diseases of the Nails and Their Management. 3rd ed. Malden, MA: Blackwell 2; 2001. p. 596—601.
18. Bhaskaranand K, Navadgi BC. Glomus tumour of the hand.J Hand Surg Br 2002;27:229—31. 27B(3): 229-231, 2002.
19. Heim U, Hänggi W. Subungual glomus tumors. Value of the direct dorsal approach. Ann Chir Main 1985;4:51—4.
20. M. Madhar, H. Elhaoury, R. Chafik, H. Saidi, T. Fikry. Les tumeurs glomiques sous unguéales : à propos de 34 cas. Revue de chirurgie orthopédique et traumatologique. Volume 97, Issue 7, November 2011, Page S268.
21. Varian J.P., Cleak D.K.: Glomus tumors of the hand. Hand;1980, 12, 293-294.
22. Mathis W.H., Schulz M.D. Roentgen diagnosis of glomus tumor. Radiology, 51: 71-76, 1948.
23. Rettig A.G., Strickland L.W:Glomus tumor of the digit. J. Hand surg. 1977; 2 ; 261-265.
24. Li QL, Zhang JF, Li HB. Early diagnosis and microsurgical treatment of hand glomus tumor in 30 female cases. Zhongguo Gu Shang. 2008;21:381—382 [Chinese].
25. Chen SH, Chen YL, Cheng MH, Yeow KM, Chen HC, Wei FC. The use of ultrasonography in preoperative localization of digital glomus tumors. Plast Reconstr Surg. 2003;112:115—119.
26. M. Benchakroun, O. Zaddoug, M. Boussouga, J. Boukhris, A. Jaafar Traitement des récides de tumeurs glomiques par sclérothérapie percutanée Journal des Maladies Vasculaires (2013) 38, 206—209.