

**Case Report****A Mislead Human Bite Cause a Septic Arthritis with Articular Destruction of the Fifth Metacarpophalangeal Joint: A Case Report and Review of the Literature**Naoufal Elghoul<sup>1\*</sup>, Ali Zine<sup>2</sup>, Abdeloihab Jaafar<sup>2</sup><sup>1</sup>Resident in Orthopedic Surgery and Traumatology, Department of Orthopedic Surgery and Traumatology, Military Hospital Mohammed V (HMIMV), Faculty of Medicine and Pharmacy, University Mohammed V, BP 10100 Rabat, Morocco<sup>2</sup>Professor in Orthopedic Surgery and Traumatology, Department of Orthopedic Surgery and Traumatology, Military Hospital Mohamed V (HMIMV), Faculty of Medicine and Pharmacy, University Mohammed V, BP 10100 Rabat, Morocco**Corresponding Author:** Dr. Elghoul Naoufal, E-mail: naoufal-elghoul@um5.ac.ma**ARTICLE INFO***Article history*

Received: March 07, 2019

Accepted: June 16, 2019

Published: July 31, 2019

Volume: 7 Issue: 3

Conflicts of interest: None

Funding: None

**Key words:**

Human Bite,

Arthritis,

Metacarpophalangeal Joint

**ABSTRACT**

Due to severe and fatal complications that can cause the human bite injuries to the joint; these injuries were described as “the cancer of the hand”. Human bites are less common than domestic animal bites, accounting for only 2% of hand bites. Moreover, if a human bite wound occurred in the hand, it may lead to severe infection as septic arthritis and osteomyelitis which its incidence account about only 2%. Herein, we report a rare case of a 22 years old man who presented a “minor” wound of the hand due to clenched fist human bite, managed initially inadequately leading to massive destruction of the fifth metacarpophalangeal joint, prompting the patient to undergo surgery. In the operating theater, we realized a debridement of devitalized tissue, collection of bacteriological samples and we curetted the joint surfaces along with copious irrigation with saline serum (2 liters). One gram of Amoxicillin-clavulanic acid were administrated after realizing bacteriological samples then one gram every eight hours. The wound was left open and closed secondary. Then, a dressing with betadine was applied followed by careful clinical and biological daily monitoring along with an early postoperative range of motion. At the last follow up, the patient showed no sign of infection with no pain but he kept a residual stiffness of his fifth finger. Through this observation, we emphasize that physicians should be alert about the danger if this injury is underestimated.

**INTRODUCTION**

Mammalian bites represent 1% of emergency room visits annually in the United States (1). Human bites are less common than domestic animal bites, accounting for only 2% of hand bites (2). If it occurred in the hand, it may lead to severe infection as septic arthritis and osteomyelitis, which its incidence account about only 2% (3). Herein, we report a rare case that illustrate the fatality if this type of injury is disregarded and how it should be best managed.

**CASE PRESENTATION**

A 22 years old man was admitted into the emergency department with swelling and pain of the left hand. He reported to sustain an injury from felt on hand three days ago with open skin. On admission, the emergency physician has requested a radiograph of the hand. Then he concluded to simple abrasion due to felt on the hand. The wound was dressed superficially; no debridement was performed and a short course of oral antibiotics was prescribed. At home, he apparently

did well, but he continued to experience dull aching pain over the wound calmed partially by paracetamol (taken from proper initiation of the patient). This persistent of pain obliged the patient to return to the emergency department. Thus, on admission, at 16 days from the incident, he presented, in the dorsum of the hand, a 8 mm circumferential wound over the fifth metacarpophalangeal joint with peeling skin and swelling around along with discharging pus (Figure 1a).

At this follow up of visit, patient reported that the cause of injury were a clenched fist in the incisor tooth of the adverse in a fight. The white blood count, sedimentation rate and C-reactive protein were normal. A radiograph of the hand was obtained; it showed an erosive bones with destruction of the fifth metacarpophalangeal joint (Figure1b) prompting the patient to undergo surgery.

In the operating theater, under a brachial plexus block along with tourniquet control in order to allow bloodless field. An S-shaped incision over both the dorsum of the metacarpophalangeal joint and the wound was performed. The exploration found that the capsule was violated with bone and joint destruction and partial lesion of the extensor mechanism (Figure 2c).

Then, we realized a debridement of devitalized tissue, collection of bacteriological samples and we curetted the joint surfaces along with copious irrigation with saline serum (2 liters). One gram of Amoxicillin-clavulanic acid were administrated after we realized bacteriological samples then one gram every eight hours. The wound was left open. Then, a dressing with betadine was applied followed by careful clinical and biological monitoring daily.

On the first day post-operative cares, the patient was afebrile with no necrosis or purulent discharge. A neurovascular examination was normal. Biological findings showed a normal c-reactive protein and white blood cell count.

Two days later, bacteriological samples found evidence of Staphylococcus species and S. aureus and Escherichia coli sensitive to amoxicillin + clavulanic acid associated to ciprofloxacin. The wound was closed secondary (Figure 2d).

On five days post-operative cares, the patient was discharged with a prescription for a course of 15 days

amoxicillin-clavulanic acid with ciprofloxacin treatment, to be reviewed weekly and counseled to return immediately if symptoms worsen.

At the last follow up of 12 months, the patient showed no sign of infection with no pain but a residual stiffness of his fifth finger (Figure 3). This residual stiffness did not prevent him from carrying out his activities.

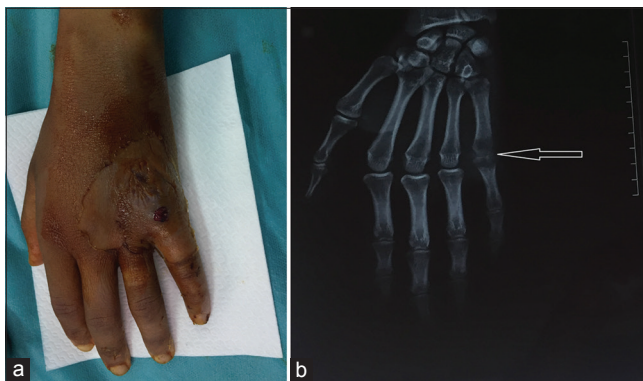
## DISCUSSION

Due to severe and fatal complications that can cause the clenched fist human bite injuries to the joint; these injuries were described as “the cancer of the hand” (4). *The wounds followed bites, particularly human bites, are frequently seen as minor injuries. Moreover, they are often improperly managed and so they may cause serious complications.* Human bite injuries of the hand occur when human teeth indent the skin. They may result from a direct bite or from striking a fist into the opponent’s teeth usually in a fight. Most often, the clenched fist injury is localized on the third metacarpophalangeal joint (5). In our patient, we found an eight millimeters circumferential wound over the fifth metacarpophalangeal joint of the hand due to clenched fist injury. As known, the oral cavity is the home for a number of polymicrobes. Human saliva contains a number of  $10^8$  microbes/ml (5). The most common bacteria cultured from bite wounds are Streptococcus, Staphylococcus, E. corrodens, Fusobacterium, Peptostreptococcus, Candida and anaerobies (3-6). Mixed aerobic and anaerobic infection is the most frequent infection (3). In our case, we found in bacteriological samples evidence of Staphylococcus species, Staphylococcus aureus and Escherichia coli sensitive to amoxicillin-clavulanic acid with ciprofloxacin. The laboratory tests should be realized (eg complete blood count, CRP/PCT, blood cultures) and radiograph is mandatory in such situation. The management protocol of human bite wounds include copious irrigation with saline, removal of foreign bodies, excisional and extended debridement of the devitalized tissue along with administration of targeted antibiotics (1-7). The wounds should not be sutured initially and closed by secondary intention (8). In Our Case, we followed the same managing protocol. Postoperative management of these wounds should include elevation of the hand, wound care, antibiotics, physiotherapy along with a careful follow-up to review wound healing, to monitor for signs of infection and patient should be alerted to return immediately if symptoms worsen (7-8).

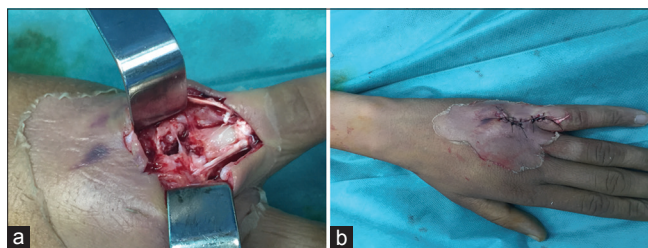
At last, overlooking a human bite on the hand increases the risk of developing serious complications that may compromise definitively its function.

## CONCLUSION

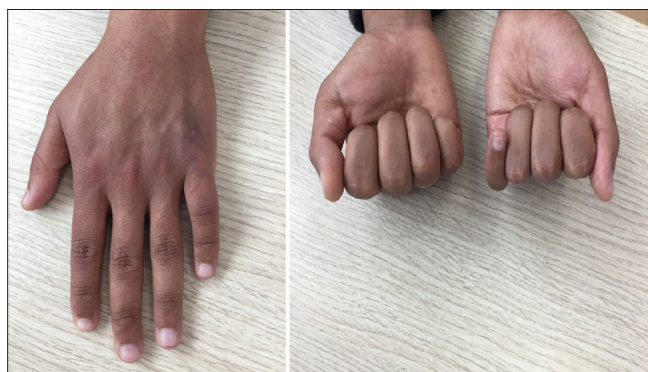As it showed our case, human bites of the hand cause small wounds that are often incorrectly treated as “minor” injuries. A delay in diagnosis or treatment is associated with an unsatisfactory outcome. That is why, the combination of an accurate and early diagnosis, meticulous debridement, efficient cleaning in concert with appropriate antibiotics along with early postoperative range of motion may avoid a serious complication and promote a good outcome.



**Figure 1.** (a) Clinical aspect of the wound due to clenched fist human bite (b) Radiograph of the hand showed an erosive bones with destruction of the fifth metacarpophalangeal joint (white arrow)



**Figure 2.** (a) The capsule was violated with bone and joint destruction and partial lesion of the extensor mechanism (b) Secondary closure after 2 days



**Figure 3.** Clinical aspect at a follow up of 12 months

**ACKNOWLEDGEMENTS**

Nil.

**REFERENCES**

1. Nakamura Y,]Daya M. Use of appropriate antimicrobials in wound management. *Emerg Med Clin North Am.* 2007;25:159-76.
2. Callaham, Michael L. Human and animal bites. *Adv Emerg Nurs J* 1982; 4(1): 1-15.
3. Talan D.A., Abrahamian F.M., Moran G.J. Clinical presentation and bacteriologic analysis of infected human bites in patients presenting to -emergency departments. *Clin Infect Dis.* 2003; 37:1481-1489.
4. Hultgen JF. Partial gangrene of the left index finger caused by the symbiosis of the fusiform bacillus spirochaetadenticola. *J Am Med Assoc.* 1910, 55: 887-8.
5. Perron A.D., Miller M.D., Brady W.J. Orthopedic pitfalls in the ED: fight bite. *Am J Emerg Med.* 2002; 20:114-117.
6. Evaldson G, Heimdahl A, Kager L, Nord CE. The normal human anaerobic microflora. *Scand J Infect Dis Suppl.* 1982; 35: 9-15.
7. Mennen U, Howells CJ. Human fight-bite injuries of the hand a study of 100 cases within 18 months. *J Hand Surg* 1991; 16(4): 431-435.
8. Cartotto RC. Managing human bite infections of the hand. *Can Fam Physician.* 1986; 32: 593-6.