

## Review Article

## Accuracy of MRI Sequences in Detecting Multiple Sclerosis (MS) Lesions: A Systematic Review

Abdullah Dhaifallah Almutairi\*, Rozi Mahmud, Subapriya Suppiah, Hasyma Abu Hassan

Department of Imaging, Faculty of Medicine and Health Sciences, University Putra Malaysia, Malaysia

Corresponding Author: Abdullah Dhaifallah Almutairi, E-mail: alrha123@hotmail.com

## ARTICLE INFO

## Article history

Received: January 14, 2019

Accepted: March 26, 2019

Published: April 30, 2019

Volume: 7 Issue: 2

Conflicts of interest: None

Funding: None

## Key words:

Magnetic Resonance Imaging,  
Multiple Sclerosis, Lesions

## ABSTRACT

**Introduction:** Multiple sclerosis (MS) is one of the chronic autoimmune central nervous system disorder that characterized by demyelination of axon in brain cortex and the other grey and white matter regions and it makes several symptoms. Magnetic Resonance Imaging (MRI) with high sensitivity is the most important preclinical tool for the diagnosis of MS. The aim is to conduct systematic review studies carried out on accuracy of MRI sequences in detecting Multiple Sclerosis (MS) lesions. **Methods:** This study was systematic review. The related studies accomplished about using MRI in detecting MS lesions in worldwide included by searching in database and journal websites, including PubMed, Google Scholar and Medline. These articles searched by main keywords such as MRI, MS, lesions, sequence, and detecting. **Conclusion:** Our reviewing study showed that Double Inversion Recovery (DIR) Sequence in MRI has a high sensitivity to detect of lesion of MS. Furthermore, we recommend that the physicians add DIR sequence in routine MR protocols for diagnostic MS in patients.

## INTRODUCTION

Multiple sclerosis (MS) is one of the chronic autoimmune central nervous system disorder (1). MS is characterized by demyelination of axon in brain cortex and the other grey and white matter regions and it makes several symptoms such as pain, mobility disorders, poor visualization, spasticity, weakness, ataxia, and bladder symptoms and cognition impairment that can get worse over time (2–4). The prevalence of the MS varies in all over the world but the studies have shown that MS is more common disease in Europe, the United States, Canada, New Zealand, and parts of Australia that Asia and Africa (5,6). So that this disease involves about 100 cases per 100,000 individual in a population in North America and Europe but in Asia and Africa involves about 2 cases per 100,000 individual in a population and it is noteworthy that it is the highest prevalence in women from 25 to 35 years old (5).

The etiology of MS is not yet clear but the studies have shown that multifactorial such as genetic and environmental factors influence the risk of MS (5,7). From these risk factors, environmental factors are modifiable such as smoking, sun exposure, deficiency of vitamin D, and obesity (8,9).

In research and clinical practices are used clinical, imaging, and laboratory evidence for diagnostic MS (10) from these, Magnetic Resonance Imaging (MRI) with high sensitivity is the most important preclinical tool for the diagnosis of MS and it can detect and monitor the progress of MS (11). MRI can assess anatomical structures in three orient-

ed sectional slices such as axial, coronal and sagittal (11). Based on previous studies, however, there is poor correlation between extent of lesions showed by MRI and the clinical symptoms of the MS; using MRI technique is not considered to diagnostic MS in many imaging centers. Therefore, it is necessary finding a more sensitive and specific tool for diagnosing of the MS. Based on this goal, we need to retrospective study to compare and determine the most sensitive MRI sequences for characterizing MS disease patients.

## Objective

The aim is to conduct systematic review studies carried out on accuracy of MRI sequences in detecting Multiple Sclerosis (MS) lesions.

## MATERIALS AND METHODS

The design of this study was systematic review. The related studies accomplished about using MRI in detecting MS lesions in worldwide included by searching in database and journal websites, including PubMed, Google Scholar and Medline. These articles searched by main keywords such as MRI, MS, lesions, sequence, and detecting. From all studies, 10 original English articles that appeared in publications from December 2010 to December 2018 included in this study. The exclusion criteria were: articles that were

not focused on using MRI in detecting MS lesions and articles that had assessed its effect on patients with MS before the 2010 year.

The protocol of finding related study was as following, after searching studies by keywords in databases, all of the studies were entered in endnote, then removed duplicate. After that titles and abstracts of the articles was checked. In next step, full text of the related studies was screened. Figure 1 shows the flowchart of the study selection criteria. See details of method in figure 1.

## RESULTS

Based on inclusion criteria, totally 10 studies were entered in this review. All of studies were focused on using MRI in detecting MS lesions. Details of these studies explained below.

Birgit Simon et al performed a study in 2010 year on Thirty-four MS patients to detect the accuracy of double inversion recovery (DIR) for showing cortical lesions. They found that the FLAIR and T2-weighted images could not detect more cortical lesions but 3 T could significantly detect lesion in the infratentorial, periventricular and juxtacortical white matter.

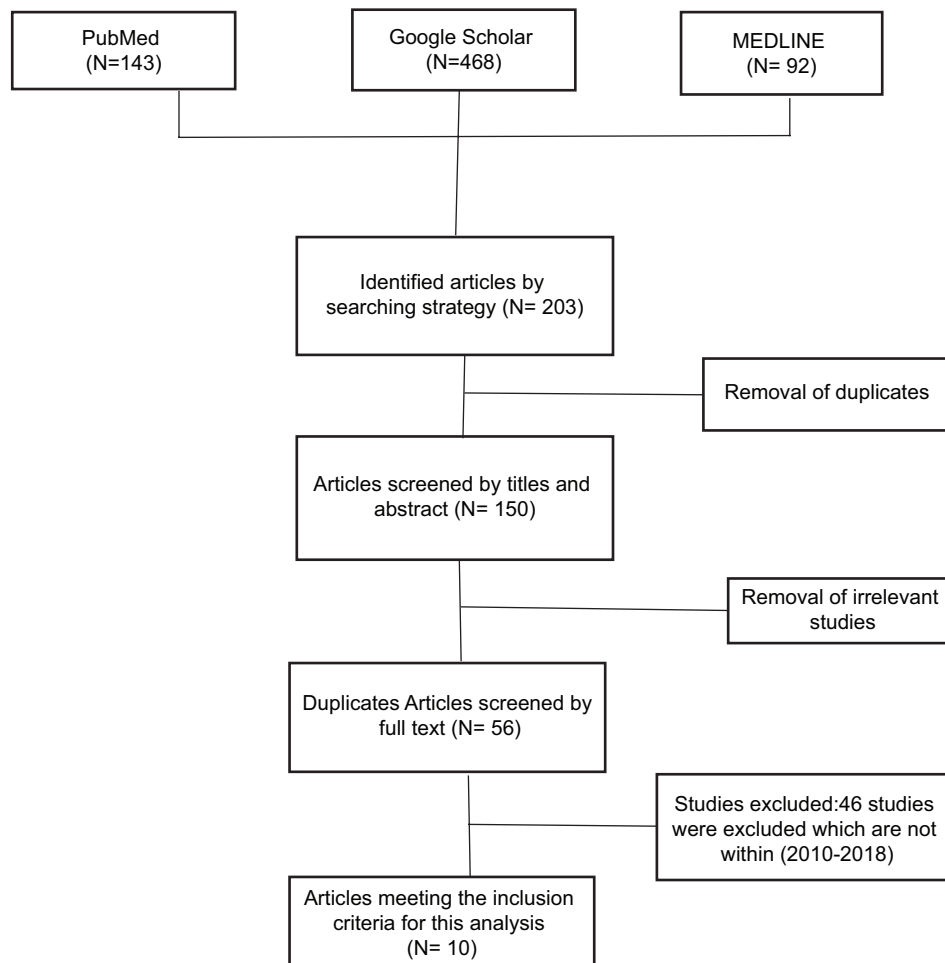
Cristina Philpott et al examined the accuracy of T2, standard STIR and T1 weighted STIR sequence in detection of plaques in MS patient in 2011 year (12). They entered all

MS patient with cervical cord lesions that presented to their institution in duration of 5 months. They used T2, FSE, STIR and the recommended T1 STIR for their samples. Finally, they found that T1 STIR had more accuracy to detect lesions than both the traditional STIR and T2 sequences ( $p < 0.05$ )

Vural et al. in 2013 year performed the study to compare DIR and Conventional Magnetic Resonance Brain Imaging in MS patients (13). Totally, they used DIR, FLAIR and T2-weighted magnetic resonance for their participant. Thirty-four patients (20 females and 14 males) entered into this study. After intervention, they found that DIR had more sensitivity to detect lesions in both white matter and grey matter than FLAIR and T2.

As well as Elnekeidy et al. in 2014 year examined the ability of DIR to detect of cortical and white matter brain lesions in multiple sclerosis (14). They selected fifteen patients with MS in this study. The intervention was including DIR, FLAIR, and T2-weighted image (T2WI) sequences. They assessed lesion in normal-appearing gray matter (NAGM), normal-appearing white matter (NAWM), and cerebrospinal fluid (CSF). After intervention, they found that the number of lesions detected by DIR was significantly more compared to T2WI or FLAIR.

In addition Pierre Kolber et al. in 2015 year performed the study to detect of cortical lesions with DIR and FLAIR in MS patients (15). Total their participant was 122 patients that



**Figure 1.** Flow diagram of the selection process of the study for systematic review on Accuracy of MRI Sequences in Detecting Multiple Sclerosis (MS) Lesions in 2010- 2018

they divided them in two groups. The main their finding was that 3D FLAIR and 3D DIR sequences both of them could detect more cortical lesions in RRMS patients than CIS.

As well as Abidi et al. examined the value of DIR sequence to detect of brain MS lesions in 2017 (16). Their study was cross sectional and they entered 55 patients in their study from May 2016 to February 2016. They examined DIR, FLAIR, and T2-weighted turbo spin echo (T2W\_TSE) sequences on field of view (FOV), matrix, slice thickness, voxel size, and number of signal averaging (NSA). They found that DIR could find more intracortical lesions than FLAIR and T2W\_TSE.

Another study was done by Gulhan Ertan et al. in 2018 to compare the efficiency of 3D DIR Sequence and 3D FLAIR in detection of intracervical, mixed, juxtacortical (JX), and deep grey matter (GM) Cortical Lesions in MS patients (17). Their sample size was 24 patients (9 males, 15 females; mean age  $34.4 \pm 12.0$ ). Their main result was that DIR could detect significantly more intracortical lesions ( $p < 0.001$ ) and GM lesions (intracortical +mixed) ( $p < 0.001$ ).

Furthermore, Wang et al performed the study in 2018 year to compares T2 weighted spin echo, 2D, and 3D fluid-attenuated inversion recovery to detect of the infratentorial lesion (18). Total their participant was 85 patients. Contrast-to-noise and signal-to-noise ratios were measured for 25 MRIs. They found that 3D FLAIR could detect significantly

more lesions than 2D ( $p < 0.001$ ) and T2-weighted spin echo ( $p < 0.001$ ).

Also, Han et al performed study to investigate of grey matter abnormalities detected by double inversion recovery sequences and diffusion tensor MRI at 3.0 Tesla in MS patients in 2018 year (19). They enrolled 20 relapsing remitting MS (RRMS) patients and 20 healthy control. They examined the effect of DIR and DTI MRI on detection of the cortical lesions and normal-appearing grey matter (NAGM) in both groups. As well as the participants completed the Mini-Mental State Examination (MMSE) and Expanded Disability Status Scale (EDSS). The main result of this study was that the NAGM in patient group was significantly different compared with the control group. Furthermore, there was negative correlation between the NAGM FA with NAGM MD values of the MS patients and the MMSE score. Nevertheless, there was positive correlation between the NAGM FA and NAGM MD values with the EDSS score.

Finally, Silvia De Santis et al assessed the Characterizing Microstructural Tissue Properties with Diffusion MRI at 7 T and 3 T in MS patients to identify the best protocol and biomarker in the inflammatory lesions in 2018 year (20). In this study, seven MS patients and six healthy controls assessed with MRI. They found that Multi-shell diffusion MRI at both high (3 T) and ultra-high fields (7 T) increased the ability to detect axonal pathology in MS patients.

NO	Authors & Years	Size	Region	Finding	Summary
1	Gulhan Ertan et al. (2018)	24 patients (9 males, 15 females; mean age $34.4 \pm 12.0$ (16-69) were retrospectively evaluated	Istanbul Turkey	More lesions were detected by the DIR sequence compared to the FLAIR sequence in all regions except for thalamus	The DIR sequence is superior to the FLAIR sequence in the detection of intracortical and GM lesions. In addition, the mixed lesion load on the DIR sequence is correlated with cerebral atrophy.
2	Abdelaziz M. Elnekeidy et al. (2014)	Fifteen patients with relapsing remitting MS were included in this study	Egypt	DIR showed significantly more MS lesion load overall when compared to T2WI or FLAIR.	DIR sequence is valuable in the imaging workup of MS as it can detect more MS lesions compared to the T2W and FLAIR sequences, in all anatomical locations.
3	Zahra Abidi et al. (2017)	55 patients were admitted	Iran	More lesions in number and size were depicted on the DIR sequence compared with FLAIR and T2W_TSE.	An increasing total number of MS lesions can be detected by DIR sequence. The study recommend adding DIR sequence in routine MR protocols for MS patients.
4	Kevin Y. Wang, Tomas A. Uribe, Christie M. Lincoln (2018)	Two board-certified radiologists independently reviewed and counted infratentorial lesions from 85 brain MRIs in patients with clinically definite multiple sclerosis and concurrent 3D, 2D fluid-attenuated inversion	United state	The number of lesions on 3D fluid-attenuated inversion recovery was significantly higher than those on	The 3D fluid-attenuated inversion recovery sequence addresses the disadvantage of poor infratentorial lesion detection on 2D, while still maintaining the advantage over T2-weighted spin echo in the detection

		recovery, and T2-weighted spin echo sequences		2D ( $p < 0.001$ ) and T2-weighted spin echo ( $p < 0.001$ )	of lesions adjacent to the cerebrospinal fluid
5	G. VURAL et al. (2013)	Thirty-four patients with MS (20 females and 14 males) were included in this study.	Turkey	DIR images showed more intracortical and mixed white matter-grey matter lesions in comparison with both FLAIR and T2 sequences	IR brain imaging had the highest sensitivity in the detection of cortical and mixed white matter - grey matter lesions, compared with FLAIR and T2 sequences. In addition, the lesions obtained with DIR images were more easily visualized.
6	Pierre Kolber et al. (2015)	Total their participant was 122 patients	Germany	Cortical lesions imaged with 3D FLAIR and 3D DIR sequences are found more frequently in RRMS patients than CIS and may be a correlate for mild neuropsychological pathology.	CIS image with 3D FLAIR and 3D DIR sequences are found more frequently in RRMS patients than CLS.
7	Birgit Simon et al. (2010)	Thirty-four patients with clinically isolated syndromes or definite MS were included	Germany	They observed significantly higher numbers of lesions involving the cortex at 3 T using a DIR sequence	DIR brain MR imaging at 3 T substantially improves the sensitivity of the detection of cortical lesions compared with the standard magnetic field strength of 1.5 T.
8	X. Han et al. (2018)	Twenty relapsing remitting MS (RRMS) patients and 20 healthy control were enrolled in this study	China	The NAGM of the patient group had average MD and FA values that were significantly different compared with the control group	The NAGM of MS patients has microstructural damages. The extent of such damage was correlated with the number of cortical lesions. The severity of the damage also correlated with increased severity of cognitive impairment and neural defects.
9	Silvia De Santis et al. (2018)	This study has Seven MS patients and six age-matched healthy controls	Germany	Multi-shell diffusion acquisitions increased the ability to detect axonal pathology occurring in MS brain tissue compared to conventional DTI in a small pilot study, also under clinical settings	Multi-shell diffusion MRI at both high (3 T) and ultra-high fields (7 T) are viable options for imaging tissue change in MS lesions and normal appearing WM, while higher b-values are not beneficial for MS under the tested short-time (10 min acquisition) conditions.
10	Cristina Philpott et al. (2011)	Their participants were patients with multiple sclerosis with cervical cord lesions that they presented to their institution over a period of 5 months	Australia	They found that the T2 sequence was not more effective in detecting lesions than the traditional STIR and T1 weighted STIR, with 10% of lesions not detected using statistical analysis ( $p < 0.05$ ).	Earlier findings of the traditional STIRs increased sensitivity versus the T2 sequence. However, the new "T1 weighted STIR" appears to be even more sensitive than both these sequences showing potential promise as an alternative method to monitor demyelinating plaques of MS.

## CONCLUSION

MS is a common inflammatory central nervous disorder that it more involves young individuals and can make severe symptom and disrupts normal life of patients. Furthermore, it is important to find a para clinical way with high sensitivity for diagnosing this disease early. In recently year researchers examined the. Our reviewing study about accuracy of MRI to detect this disease showed that Double Inversion Recovery (DIR) Sequence in MRI has a high sensitivity to detect of lesion of MS. Furthermore, we recommend that the physicians add DIR sequence in routine MR protocols for diagnostic MS in patients.

## REFERENCE

- Lassmann H. Multiple sclerosis pathology. *Cold Spring Harbor perspectives in medicine*. 2018;8(3):a028936.
- Geurts JGG, Barkhof F. Grey matter pathology in multiple sclerosis. *The Lancet Neurology*. 2008;7(9):841–51.
- Zajicek J, Fox P, Sanders H, Wright D, Vickery J, Nunn A, et al. Cannabinoids for treatment of spasticity and other symptoms related to multiple sclerosis (CAMS study): multicentre randomised placebo-controlled trial. *The lancet*. 2003;362(9395):1517–26.
- Kargarfard M, Shariat A, Ingle L, Cleland JA, Kargarfard M. A randomized controlled trial to examine the impact of aquatic exercise training on functional capacity, balance, and perceptions of fatigue in female patients with multiple sclerosis. *Archives of Physical Medicine and Rehabilitation*. 2017;
- Ascherio A, Munger KL. Environmental risk factors for multiple sclerosis. Part I: the role of infection. *Annals of neurology*. 2007;61(4):288–99.
- Ascherio A, Munger KL. Environmental risk factors for multiple sclerosis. Part II: Noninfectious factors. *Annals of Neurology: Official Journal of the American Neurological Association and the Child Neurology Society*. 2007;61(6):504–13.
- Ramagopalan S V, Dobson R, Meier UC, Giovannoni G. Multiple sclerosis: risk factors, prodromes, and potential causal pathways. *The Lancet Neurology*. 2010;9(7):727–39.
- Alfredsson L, Olsson T. Lifestyle and environmental factors in multiple sclerosis. *Cold Spring Harbor perspectives in medicine*. 2018;a028944.
- Amato MP, Derfuss T, Hemmer B, Liblau R, Montalban X, Soelberg Sørensen P, et al. Environmental modifiable risk factors for multiple sclerosis: report from the 2016ECTRIMS focused workshop. *Multiple Sclerosis Journal*. 2018;24(5):590–603.
- Thompson AJ, Banwell BL, Barkhof F, Carroll WM, Coetzee T, Comi G, et al. Diagnosis of multiple sclerosis: 2017 revisions of the McDonald criteria. *The Lancet Neurology*. 2018;17(2):162–73.
- Filippi M, Rocca MA, Ciccarelli O, De Stefano N, Evangelou N, Kappos L, et al. MRI criteria for the diagnosis of multiple sclerosis: MAGNIMS consensus guidelines. *The Lancet Neurology*. 2016;15(3):292–303.
- Philpott C, Brotchie P. Comparison of MRI sequences for evaluation of multiple sclerosis of the cervical spinal cord at 3 T. *European journal of radiology*. 2011;80(3):780–5.
- Vural G, Keklikoğlu HD, Temel Ş, Deniz O, Ercan K. Comparison of double inversion recovery and conventional magnetic resonance brain imaging in patients with multiple sclerosis and relations with disease disability. *The neuroradiology journal*. 2013;26(2):133–42.
- Elnekeidy AM, Kamal MA, Elfatratry AM, Elskeikh ML. Added value of double inversion recovery magnetic resonance sequence in detection of cortical and white matter brain lesions in multiple sclerosis. *The Egyptian Journal of Radiology and Nuclear Medicine*. 2014;45(4):1193–9.
- Kolber P, Montag S, Fleischer V, Luessi F, Wilting J, Gawehn J, et al. Identification of cortical lesions using DIR and FLAIR in early stages of multiple sclerosis. *Journal of neurology*. 2015;262(6):1473–82.
- Abidi Z, Faeghi F, Mardanshahi Z, Mortazavi H. Assessment of the diagnostic accuracy of double inversion recovery sequence compared with FLAIR and T2W\_TSE in detection of cerebral multiple sclerosis lesions. *Electronic physician*. 2017;9(4):4162.
- Ertan G, Arici O, Ulus S, Metin B. Efficiency of Double Inversion Recovery (DIR) Sequence in the Evaluation of Supratentorial Cortical Lesions in Multiple Sclerosis. *NeuroQuantology*. 2018;16(3).
- Wang KY, Uribe TA, Lincoln CM. Comparing lesion detection of infratentorial multiple sclerosis lesions between T2-weighted spin-echo, 2D-FLAIR, and 3D-FLAIR sequences. *Clinical imaging*. 2018;51:229–34.
- Han X, Wang X, Wang L, Zheng Z, Gu J, Tang D, et al. Investigation of grey matter abnormalities in multiple sclerosis patients by combined use of double inversion recovery sequences and diffusion tensor MRI at 3.0 Tesla. *Clinical radiology*. 2018;73(9):834–e17.
- De Santis S, Bastiani M, Droby A, Kolber P, Zipp F, Pracht E, et al. Characterizing microstructural tissue properties in multiple sclerosis with diffusion MRI at 7 T and 3 T: the impact of the experimental design. *Neuroscience*. 2018;